A 25-year-old woman comes to the emergency department due to 2 days of abdominal pain and bloody diarrhea. A few days ago, she attended a church barbeque party. The patient lives alone and has no medical problems. She does not know if anyone else at the party developed similar symptoms. Her temperature is 37.1 C (98.8 F), blood pressure is 119/76 mm Hg, pulse is 92/min, and respirations are 16/min. There is abdominal tenderness with no rebound or guarding. Guaiac-positive bloody stools are detected on rectal examination. Stool cultures reveal an *Escherichia coli* strain that does not produce glucuronidase and does not ferment sorbitol on sorbitol-containing MacConkey agar. Which of the following best describes the mechanism of action of the toxin produced by these bacteria?

- A. Activates adenylate cyclase
- B. Activates guanylate cyclase
- C. Disrupts the cellular cytoskeleton
- D. Inactivates elongation factor-2
- E. Inactivates ribosomal subunits

Submit

A 25-year-old woman comes to the emergency department due to 2 days of abdominal pain and bloody diarrhea. A few days ago, she attended a church barbeque party. The patient lives alone and has no medical problems. She does not know if anyone else at the party developed similar symptoms. Her temperature is 37.1 C (98.8 F), blood pressure is 119/76 mm Hg, pulse is 92/min, and respirations are 16/min. There is abdominal tenderness with no rebound or guarding. Guaiac-positive bloody stools are detected on rectal examination. Stool cultures reveal an *Escherichia coli* strain that does not produce glucuronidase and does not ferment sorbitol on sorbitol-containing MacConkey agar. Which of the following best describes the mechanism of action of the toxin produced by these bacteria?

A. Activates adenylate cyclase (14%)

B. Activates guanylate cyclase (8%)

C. Disrupts the cellular cytoskeleton (12%)

D. Inactivates elongation factor-2 (11%)

✓ E. Inactivates ribosomal subunits (53%)

Omitted
Correct answer
E

53%
Answered correctly

03 secs
Time Spent

01/20/2020
Last Updated

Explanation

Mechanism of action of selected bacterial exotoxins		
Organism	**Toxin**	**Mechanism & effects**

Mechanism of action of selected bacterial exotoxins

Organism	Toxin	Mechanism & effects
Bacillus anthracis	Anthrax exotoxin	Edema factor: Increases cyclic AMP concentration by acting as an adenylate cyclase, causing edema & phagocyte dysfunction
		Lethal factor: Zinc-dependent protease that inhibits mitogen-activated protein kinase signaling, causing apoptosis & multisystem physiologic disruption
Bordetella pertussis	Pertussis toxin	Disinhibits adenylate cyclase through G_i ADP-ribosylation, increasing cAMP levels; causes edema & phagocyte dysfunction
	Adenylate cyclase toxin	Functions as an adenylate cyclase, increasing cAMP levels; causes edema & phagocyte dysfunction
Clostridium botulinum	Botulinum toxin	Blocks presynaptic release of acetylcholine at the neuromuscular junction, resulting in flaccid paralysis
Clostridium difficile	Toxin A	Recruits & activates neutrophils, leading to release of cytokines that cause mucosal inflammation, fluid loss & diarrhea
	Toxin B	Induces actin depolymerization, leading to mucosal cell death, bowel wall necrosis & pseudomembrane formation
Shigella dysenteriae	Shiga toxin	Halts protein synthesis by disabling the 60S ribosomal subunit, leading to intestinal epithelial cell death & diarrhea
Streptococcus	Pyrogenic exotoxin	Acts as a superantigen, inducing fever & shock; associated with scarlet fever & streptococcal toxic shock syndrome

Mechanism of action of selected bacterial exotoxins

Organism	Toxin	Mechanism & effects
Bacillus anthracis	Anthrax exotoxin	Edema factor: Increases cyclic AMP concentration by acting as an adenylate cyclase, causing edema & phagocyte dysfunction
		Lethal factor: Zinc-dependent protease that inhibits mitogen-activated protein kinase signaling, causing apoptosis & multisystem physiologic disruption
Bordetella pertussis	Pertussis toxin	Disinhibits adenylate cyclase through G_i ADP-ribosylation, increasing cAMP levels; causes edema & phagocyte dysfunction
	Adenylate cyclase toxin	Functions as an adenylate cyclase, increasing cAMP levels; causes edema & phagocyte dysfunction
Clostridium botulinum	Botulinum toxin	Blocks presynaptic release of acetylcholine at the neuromuscular junction, resulting in flaccid paralysis
Clostridium difficile	Toxin A	Recruits & activates neutrophils, leading to release of cytokines that cause mucosal inflammation, fluid loss & diarrhea
	Toxin B	Induces actin depolymerization, leading to mucosal cell death, bowel wall necrosis & pseudomembrane formation
Shigella dysenteriae	Shiga toxin	Halts protein synthesis by disabling the 60S ribosomal subunit, leading to intestinal epithelial cell death & diarrhea
Streptococcus pyogenes	Pyrogenic exotoxin	Acts as a superantigen, inducing fever & shock; associated with scarlet fever & streptococcal toxic shock syndrome
	Streptolysin O&S	Damages erythrocyte membranes, causing beta hemolysis

Clostridium botulinum	Botulinum toxin	Blocks presynaptic release of acetylcholine at the neuromuscular junction, resulting in flaccid paralysis
Clostridium difficile	Toxin A	Recruits & activates neutrophils, leading to release of cytokines that cause mucosal inflammation, fluid loss & diarrhea
	Toxin B	Induces actin depolymerization, leading to mucosal cell death, bowel wall necrosis & pseudomembrane formation
Shigella dysenteriae	Shiga toxin	Halts protein synthesis by disabling the 60S ribosomal subunit, leading to intestinal epithelial cell death & diarrhea
Streptococcus pyogenes	Pyrogenic exotoxin	Acts as a superantigen, inducing fever & shock; associated with scarlet fever & streptococcal toxic shock syndrome
	Streptolysin O&S	Damages erythrocyte membranes, causing beta hemolysis

Enterohemorrhagic *Escherichia coli* (EHEC) **O157:H7** can cause hemorrhagic colitis, most characteristically following ingestion of inadequately cooked hamburger meat. In contrast to most *E coli* strains, O157:H7 *E coli* does **not** ferment sorbitol during overnight incubation. As a result, sorbitol-containing MacConkey agar is used for isolation. Also, unlike other *E coli* strains, *E coli* O157:H7 does **not** produce glucuronidase.

EHEC elaborates a **Shiga-like toxin** virtually identical to the Shiga toxin produced by *Shigella dysenteriae*. This toxin is phage encoded, and its production is enhanced by iron deficiency. The Shiga and the Shiga-like toxins inactivate the 60s **ribosomal subunit** in human cells, leading to an inhibition of protein synthesis and eventual cell death. Infection with EHEC can also lead to hemolytic-uremic syndrome, characterized by thrombocytopenia, microangiopathic hemolytic anemia, and renal insufficiency (sometimes with uremia).

Unlike enteroinvasive *E coli*, EHEC does not invade the intestinal mucosa. Unlike enterotoxigenic *E coli* (ETEC), EHEC does not produce heat-labile toxin (LT) or heat-stable toxin (ST).

(Choice A) Toxins produced by *Bordetella pertussis* (adenylate cyclase toxin), ETEC (LT), *Campylobacter jejuni* (*C jejuni* enterotoxin), and *Vibrio*

EHEC elaborates a **Shiga-like toxin** virtually identical to the Shiga toxin produced by *Shigella dysenteriae*. This toxin is phage encoded, and its production is enhanced by iron deficiency. The Shiga and the Shiga-like toxins inactivate the 60s **ribosomal subunit** in human cells, leading to an inhibition of protein synthesis and eventual cell death. Infection with EHEC can also lead to hemolytic-uremic syndrome, characterized by thrombocytopenia, microangiopathic hemolytic anemia, and renal insufficiency (sometimes with uremia).

Unlike enteroinvasive *E coli*, EHEC does not invade the intestinal mucosa. Unlike enterotoxigenic *E coli* (ETEC), EHEC does not produce heat-labile toxin (LT) or heat-stable toxin (ST).

(Choice A) Toxins produced by *Bordetella pertussis* (adenylate cyclase toxin), ETEC (LT), *Campylobacter jejuni* (*C jejuni* enterotoxin), and *Vibrio cholerae* (choleragen toxin) result in increased intracellular cyclic AMP in intestinal mucosal cells, which leads to decreased absorption and increased secretion of sodium, chloride, and water.

(Choice B) ETEC (ST) and *Yersinia enterocolitica* (*Y enterocolitica* enterotoxin) produce toxins that increase intracellular cyclic GMP, leading to watery diarrhea and electrolyte loss.

(Choice C) *Clostridium difficile* produces an exotoxin capable of disrupting the cytoskeleton (toxin B/cytotoxin). This toxin acts by depolymerizing actin, leading to cell death.

(Choice D) Exotoxins produced by *Corynebacterium diphtheriae* (diphtheria toxin) inhibit protein synthesis in eukaryotic cells by catalyzing ADP-ribosylation of elongation factor (EF)-2, causing EF-2 inactivation.

Educational objective:
Enterohemorrhagic *Escherichia coli* O157:H7 infection is a common cause of bloody diarrhea and can lead to hemolytic-uremic syndrome. It is associated with consumption of undercooked ground beef and elaborates a Shiga-like toxin capable of inhibiting protein synthesis in colonic mucosal cells and renal endothelial cells. This particular strain of *E coli* is unable to ferment sorbitol and does not produce a glucuronidase.

Microbiology	Gastrointestinal & Nutrition	Acute diarrhea
Subject	System	Topic

Copyright © UWorld. All rights reserved.

A 6-year-old previously healthy girl is brought to the office due to diarrhea and abdominal pain. She started having watery diarrhea after a barbeque dinner 4 days ago; her stools became grossly bloody 2 days later. Her mother also had similar symptoms. The patient's temperature is 37 C (98.7 F). The abdomen is soft with mild generalized tenderness. Stool culture is performed on sorbitol-MacConkey agar and reveals sorbitol-negative colonies with biochemical properties of *Escherichia coli*. Enzyme immunoassay detects a substance capable of inhibiting protein synthesis in human cells. The substance detected in this patient is most similar to the toxin produced by which of the following bacteria?

- A. *Clostridium difficile*
- B. *Proteus mirabilis*
- C. *Pseudomonas aeruginosa*
- D. *Salmonella typhi*
- E. *Shigella dysenteriae*
- F. *Vibrio cholerae*

Submit

A 6-year-old previously healthy girl is brought to the office due to diarrhea and abdominal pain. She started having watery diarrhea after a barbeque dinner 4 days ago; her stools became grossly bloody 2 days later. Her mother also had similar symptoms. The patient's temperature is 37 C (98.7 F). The abdomen is soft with mild generalized tenderness. Stool culture is performed on sorbitol-MacConkey agar and reveals sorbitol-negative colonies with biochemical properties of *Escherichia coli*. Enzyme immunoassay detects a substance capable of inhibiting protein synthesis in human cells. The substance detected in this patient is most similar to the toxin produced by which of the following bacteria?

- A. *Clostridium difficile* (2%)
- B. *Proteus mirabilis* (0%)
- C. *Pseudomonas aeruginosa* (6%)
- D. *Salmonella typhi* (2%)
- ✓ E. *Shigella dysenteriae* (85%)
- F. *Vibrio cholerae* (2%)

Omitted
Correct answer
E

85%
Answered correctly

03 secs
Time Spent

06/22/2020
Last Updated

Explanation

Mechanism of action of selected bacterial exotoxins		
Organism	**Toxin**	**Mechanism & effects**

Mechanism of action of selected bacterial exotoxins

Organism	Toxin	Mechanism & effects
Bacillus anthracis	Anthrax exotoxin	Edema factor: Increases cyclic AMP concentration by acting as an adenylate cyclase, causing edema & phagocyte dysfunction
		Lethal factor: Zinc-dependent protease that inhibits mitogen-activated protein kinase signaling, causing apoptosis & multisystem physiologic disruption
Bordetella pertussis	Pertussis toxin	Disinhibits adenylate cyclase through G_i ADP-ribosylation, increasing cAMP levels; causes edema & phagocyte dysfunction
	Adenylate cyclase toxin	Functions as an adenylate cyclase, increasing cAMP levels; causes edema & phagocyte dysfunction
Clostridium botulinum	Botulinum toxin	Blocks presynaptic release of acetylcholine at the neuromuscular junction, resulting in flaccid paralysis
Clostridium difficile	Toxin A	Recruits & activates neutrophils, leading to release of cytokines that cause mucosal inflammation, fluid loss & diarrhea
	Toxin B	Induces actin depolymerization, leading to mucosal cell death, bowel wall necrosis & pseudomembrane formation
Shigella dysenteriae	Shiga toxin	Halts protein synthesis by disabling the 60S ribosomal subunit, leading to intestinal epithelial cell death & diarrhea
Streptococcus pyogenes	Pyrogenic exotoxin	Acts as a superantigen, inducing fever & shock; associated with scarlet fever & streptococcal toxic shock syndrome
	Streptolysin O/S	Damages erythrocyte membranes, causing beta hemolysis

Bordetella pertussis	Pertussis toxin	Disinhibits adenylate cyclase through G_i ADP-ribosylation, increasing cAMP levels; causes edema & phagocyte dysfunction
	Adenylate cyclase toxin	Functions as an adenylate cyclase, increasing cAMP levels; causes edema & phagocyte dysfunction
Clostridium botulinum	Botulinum toxin	Blocks presynaptic release of acetylcholine at the neuromuscular junction, resulting in flaccid paralysis
Clostridium difficile	Toxin A	Recruits & activates neutrophils, leading to release of cytokines that cause mucosal inflammation, fluid loss & diarrhea
	Toxin B	Induces actin depolymerization, leading to mucosal cell death, bowel wall necrosis & pseudomembrane formation
Shigella dysenteriae	Shiga toxin	Halts protein synthesis by disabling the 60S ribosomal subunit, leading to intestinal epithelial cell death & diarrhea
Streptococcus pyogenes	Pyrogenic exotoxin	Acts as a superantigen, inducing fever & shock; associated with scarlet fever & streptococcal toxic shock syndrome
	Streptolysin O&S	Damages erythrocyte membranes, causing beta hemolysis

Shiga-like toxins (Stx) (Vero cytotoxins [VT]) are produced by **enterohemorrhagic *Escherichia coli***. Stx-I (VT1) can inhibit **protein synthesis** in human cells and is closely related to the Shiga toxin produced by *Shigella dysenteriae*. It is an AB toxin (active A subunit and 5 binding B subunits). The plasmid coding for it is transmitted by a temperate bacteriophage. The B subunits, which form pentamers with a central pore, recognize specific receptors on target cells and induce receptor-mediated endocytosis and toxin internalization. Subsequently, the enzymatically active A subunit is released and catalyses the removal of a specific adenine residue, thereby preventing tRNA binding to the 60S ribosomal subunit and inhibiting protein synthesis. This leads to intestinal mucosal cell death and direct toxicity to renal epithelial cells.

(Choice A) *Clostridium difficile* produces toxin A (enterotoxin) and toxin B (cytotoxin) and causes pseudomembranous colitis, most commonly in

Shiga-like toxins (Stx) (Vero cytotoxins [VT]) are produced by **enterohemorrhagic *Escherichia coli***. Stx-I (VT1) can inhibit **protein synthesis** in human cells and is closely related to the Shiga toxin produced by *Shigella dysenteriae*. It is an AB toxin (active A subunit and 5 binding B subunits). The plasmid coding for it is transmitted by a temperate bacteriophage. The B subunits, which form pentamers with a central pore, recognize specific receptors on target cells and induce receptor-mediated endocytosis and toxin internalization. Subsequently, the enzymatically active A subunit is released and catalyses the removal of a specific adenine residue, thereby preventing tRNA binding to the 60S ribosomal subunit and inhibiting protein synthesis. This leads to intestinal mucosal cell death and direct toxicity to renal epithelial cells.

(Choice A) *Clostridium difficile* produces toxin A (enterotoxin) and toxin B (cytotoxin) and causes pseudomembranous colitis, most commonly in patients recently treated with antibiotics. Toxin B depolymerizes actin filaments, causing gastrointestinal mucosal cell death.

(Choice B) *Proteus mirabilis* does not produce toxins.

(Choice C) *Pseudomonas aeruginosa* produces exotoxin A, similar in function to diphtheria toxin in that it halts human cellular protein synthesis by inhibiting elongation factor-2. The growing protein chain is unable to change positions in the ribosome to allow binding of a new tRNA, resulting in translation arrest.

(Choice D) *Salmonella typhi* (cause of typhoid fever) enters the human digestive tract orally, penetrates the intestinal mucosa, and travels to mesenteric lymph nodes, where it multiplies and is phagocytosed by macrophages within which it can survive. Typhoid fever is characterized by fever, abdominal pain, diarrhea and/or constipation, and faintly erythematous macules on the abdomen ("rose spots").

(Choice F) *Vibrio cholerae*, the causative agent of cholera, produces the enterotoxin choleragen, which acts similarly to the heat-labile toxin of enterotoxigenic *Escherichia coli*. It increases intracellular cAMP in intestinal mucosal cells, leading to decreased absorption and increased secretion of sodium, chloride, and water.

Educational objective:
Shiga-like toxins (Vero cytotoxins), produced by enterohemorrhagic *Escherichia coli*, are nearly identical to the Shiga toxin produced by *Shigella dysenteriae*. They inhibit the 60S ribosomal subunit in human cells, thereby blocking protein synthesis by preventing binding of tRNA.

Microbiology	Gastrointestinal & Nutrition	Acute diarrhea
Subject	System	Topic

A 34-year-old man comes to the emergency department due to 5 days of progressive anorexia, nausea, and abdominal pain. The patient is a known hepatitis B carrier. He admits to using IV drugs and has shared needles with other drug users on several occasions. His temperature is 37.7 C (99.9 F). Examination shows scleral icterus and mild, tender hepatomegaly. Laboratory studies are notable for highly elevated levels of liver aminotransferases and serum bilirubin and also show the following results:

Hepatitis B surface antigen	positive
Hepatitis C virus antibody	negative
HIV-1 antibody	negative
Hepatitis D RNA	positive

This patient's chronic infection assists which of the following life cycle aspects of the current infectious agent?

- A. Coating of viral particles
- B. Integration into host genome
- C. Intracellular survival
- D. Replication of viral RNA
- E. Translation of viral transcripts

Submit

A 34-year-old man comes to the emergency department due to 5 days of progressive anorexia, nausea, and abdominal pain. The patient is a known hepatitis B carrier. He admits to using IV drugs and has shared needles with other drug users on several occasions. His temperature is 37.7 C (99.9 F). Examination shows scleral icterus and mild, tender hepatomegaly. Laboratory studies are notable for highly elevated levels of liver aminotransferases and serum bilirubin and also show the following results:

Hepatitis B surface antigen	positive
Hepatitis C virus antibody	negative
HIV-1 antibody	negative
Hepatitis D RNA	positive

This patient's chronic infection assists which of the following life cycle aspects of the current infectious agent?

- ✓ A. Coating of viral particles (39%)
- B. Integration into host genome (17%)
- C. Intracellular survival (11%)
- D. Replication of viral RNA (25%)
- E. Translation of viral transcripts (6%)

Omitted
Correct answer
A

39%
Answered correctly

02 secs
Time Spent

06/02/2020
Last Updated

Omitted
Correct answer
A

39%
Answered correctly

02 secs
Time Spent

06/02/2020
Last Updated

Explanation

Often referred to as the delta agent, **hepatitis D virus** (HDV) is a 35-nm, double-shelled particle that resembles the Dane particle of hepatitis B virus (HBV). The internal polypeptide assembly of HDV is designated **hepatitis D antigen (HDAg)**. Associated with this antigen is a very short, circular molecule of single-stranded RNA. HDAg is considered **replication defective** as it must be coated by the external coat **hepatitis B surface antigen (HBsAg)** of HBV to penetrate the hepatocyte. HDV infection can arise either as an acute coinfection with HBV or as a superinfection of a chronic HBV carrier.

(Choices B, C, D, and E) Once coated with HBsAg, HDV is able to penetrate the hepatocyte, survive within the cell, integrate into the host genome, replicate its viral RNA, and translate its genome into protein.

Educational objective:
The hepatitis B surface antigen of hepatitis B virus must coat the hepatitis D antigen of hepatitis D virus before it can infect hepatocytes and multiply.

References

- Life cycle and pathogenesis of hepatitis D virus: A review.

Microbiology	Gastrointestinal & Nutrition	Hepatitis d
Subject	System	Topic

Copyright © UWorld. All rights reserved.

A 42-year-old man comes to the physician because of dysuria and blood in his urine at the end of urination. He returned to the United States 2 weeks ago after several months touring Africa. While there, he went spelunking, bathed in the beaches and lakes, and ate the local street food. Physical examination is unremarkable. Ultrasonography reveals mild bilateral hydronephrosis and bladder wall thickening. Which of the following animals is the most likely source of this patient's infection?

- A. Bat
- B. Dog
- C. Fish
- D. Pig
- E. Sheep
- F. Snail

Submit

A 42-year-old man comes to the physician because of dysuria and blood in his urine at the end of urination. He returned to the United States 2 weeks ago after several months touring Africa. While there, he went spelunking, bathed in the beaches and lakes, and ate the local street food. Physical examination is unremarkable. Ultrasonography reveals mild bilateral hydronephrosis and bladder wall thickening. Which of the following animals is the most likely source of this patient's infection?

- A. Bat (8%)
- B. Dog (2%)
- C. Fish (12%)
- D. Pig (3%)
- E. Sheep (2%)
- ✓ F. Snail (70%)

Omitted
Correct answer
F

70%
Answered correctly

03 secs
Time Spent

03/01/2020
Last Updated

Explanation

Schistosomiasis		
***Schistosoma* species**	**Location**	**Symptoms**

Schistosomiasis		
***Schistosoma* species**	**Location**	**Symptoms**
S haematobium	• North Africa • Sub-Saharan Africa • Middle East	**Urinary schistosomiasis** • Terminal hematuria, dysuria & frequent urination • Hydronephrosis, pyelonephritis & squamous cell carcinoma of the bladder
S mansoni	• Sub-Saharan Africa • Middle East • South America • Caribbean	**Intestinal schistosomiasis** • Diarrhea & abdominal pain • Intestinal ulceration → iron deficiency anemia
S japonicum	• Asia, particularly China • Philippines • Japan	**Hepatic schistosomiasis** • Hepatomegaly, splenomegaly • Periportal fibrosis & subsequent portal hypertension

This patient most likely has **schistosomiasis** caused by *Schistosoma haematobium*. Humans acquire schistosomiasis via contact with infected freshwater. Infection is not possible in the United States due to absence of the specific **freshwater snails** that incubate the infectious larvae.

Once released into the environment, the larvae can penetrate **intact human skin** and subsequently travel to the **liver** where they mature into adults over a period of several weeks. After maturation, the adult worms migrate to specific destinations: the mesenteric venules of the **intestine** (*S japonicum* and *S mansoni*) or the **urinary bladder** venous plexus (*S haematobium*). The adult worms remain in these blood vessels for life (5-30 years), adhering to the vessel wall with suckers and releasing eggs into circulation. Eggs released by *S japonicum* and *S mansoni* have a tendency to penetrate the bowel wall and be excreted in the feces. They also frequently traverse the portal venous system and lodge in the liver. *S haematobium* eggs tend to pierce the vesical and ureteral walls and be expelled in the urine. On exposure to freshwater, these eggs release larvae that can infect snails and perpetuate the life cycle.

The clinical manifestations of schistosomiasis result from a **T_H2-mediated** granulomatous response directed against the eggs that is composed of

tendency to penetrate the bowel wall and be excreted in the feces. They also frequently traverse the portal venous system and lodge in the liver. *S haematobium* eggs tend to pierce the vesical and ureteral walls and be expelled in the urine. On exposure to freshwater, these eggs release larvae that can infect snails and perpetuate the life cycle.

The clinical manifestations of schistosomiasis result from a **T_H2-mediated** granulomatous response directed against the eggs that is composed of infiltrating T_H2 cells, eosinophils, and M2 macrophages. This ultimately leads to the development of marked fibrosis and **ulceration and scarring of the bowel or bladder/ureters** (depending on the species). Eggs that settle into the presinusoidal radicals of the portal vein can cause **periportal "pipestem" fibrosis** (pathognomonic for hepatic schistosomiasis).

(Choice A) Bats are a major reservoir for the rabies virus.

(Choices B and E) The dog tapeworm *Echinococcus granulosus* is the most common cause of hydatid cysts in humans. Disease can occur following ingestion of foods contaminated with dog feces. Sheep are an intermediate host in this parasite's life cycle.

(Choice C) Infection with the human tapeworm *Diphyllobothrium latum* occurs due to the ingestion of larvae from raw freshwater fish. Disease classically results in vitamin B12 deficiency and megaloblastic anemia.

(Choice D) Human tapeworm infections caused by *Taenia solium* occur following consumption of larvae in infected undercooked pork. Cysticercosis is a disease caused by the larval stage of the organism following ingestion of eggs found in the excrement of *T solium* tapeworm carriers.

Educational objective:
Humans acquire schistosomiasis via contact with freshwater sources that contain snails infected with *Schistosoma* larvae. *S japonicum* and *S mansoni* cause intestinal and hepatic schistosomiasis, and *S haematobium* causes urinary schistosomiasis.

References

- The Schistosoma granuloma: friend or foe?

Microbiology	Renal, Urinary Systems & Electrolytes	Schistosomiasis
Subject	System	Topic

Copyright © UWorld. All rights reserved.

A 39-year-old paraplegic man with an indwelling bladder catheter comes to the emergency department complaining of 24 hours of rigors, nausea, and vomiting. His temperature is 38.9 C (102 F). Physical examination shows suprapubic and costovertebral angle tenderness. Urinalysis shows 3+ leukocyte esterase and numerous white blood cells. Urine and blood cultures grow non-lactose-fermenting Gram-negative rods. Which of the following pathogens is the most likely culprit?

A. *Enterobacter cloacae*

B. *Enterococcus faecalis*

C. *Escherichia coli*

D. *Klebsiella pneumoniae*

E. *Pseudomonas aeruginosa*

F. *Staphylococcus saprophyticus*

Submit

A 39-year-old paraplegic man with an indwelling bladder catheter comes to the emergency department complaining of 24 hours of rigors, nausea, and vomiting. His temperature is 38.9 C (102 F). Physical examination shows suprapubic and costovertebral angle tenderness. Urinalysis shows 3+ leukocyte esterase and numerous white blood cells. Urine and blood cultures grow non-lactose-fermenting Gram-negative rods. Which of the following pathogens is the most likely culprit?

A. *Enterobacter cloacae* (4%)

B. *Enterococcus faecalis* (4%)

C. *Escherichia coli* (17%)

D. *Klebsiella pneumoniae* (9%)

✓ E. *Pseudomonas aeruginosa* (61%)

F. *Staphylococcus saprophyticus* (2%)

Omitted
Correct answer
E

61%
Answered correctly

02 secs
Time Spent

05/07/2020
Last Updated

Explanation

Patients with indwelling bladder catheters are at increased risk for urinary tract infections (UTIs) caused by both typical (eg, *Escherichia coli*, *Klebsiella pneumoniae*, *Staphylococcus saprophyticus*, *Proteus mirabilis*) and opportunistic (eg, *Pseudomonas*, *Enterococcus*, other Staphylococci, fungal) organisms. This patient's culture results are consistent with *Pseudomonas aeruginosa*, the only non-lactose-fermenting, Gram-negative rod listed. It is also the only one that is oxidase positive.

Explanation

Patients with indwelling bladder catheters are at increased risk for urinary tract infections (UTIs) caused by both typical (eg, *Escherichia coli*, *Klebsiella pneumoniae*, *Staphylococcus saprophyticus*, *Proteus mirabilis*) and opportunistic (eg, *Pseudomonas*, *Enterococcus*, other Staphylococci, fungal) organisms. This patient's culture results are consistent with *Pseudomonas aeruginosa*, the only non-lactose-fermenting, Gram-negative rod listed. It is also the only one that is oxidase positive.

(Choice A) *Enterobacter cloacae* is a lactose-fermenting, Gram-negative rod characterized by extensive antibiotic resistance. It causes nosocomial infections, including UTIs, pneumonia, and surgical site infections.

(Choice B) *Enterococcus faecalis* is a Gram-positive coccus in the *Enterococcaceae* family that is a common cause of opportunistic UTIs. Vancomycin-resistant *Enterococcus* is a particularly fearsome isolate that is increasing in prevalence.

(Choice C) *Escherichia coli* is a lactose-fermenting, Gram-negative rod and the leading cause of both complicated (including catheter-associated) and uncomplicated UTIs.

(Choice D) *Klebsiella pneumoniae* is a lactose-fermenting, Gram-negative rod. It is a common cause of spontaneous bacterial peritonitis and nosocomial pneumonias as well as UTIs.

(Choice F) *Staphylococcus saprophyticus* is a catalase-positive, coagulase-negative, Gram-positive coccus that typically causes UTIs in sexually active women. It is differentiated from *S epidermidis* by being novobiocin resistant.

Educational objective:
Pseudomonas aeruginosa is an oxidase-positive, non-lactose-fermenting, Gram-negative organism. It is a common cause of urinary tract infections in patients with indwelling bladder catheters.

Microbiology	Renal, Urinary Systems & Electrolytes	Urinary tract infection
Subject	System	Topic

Copyright © UWorld. All rights reserved.

A 79-year-old woman is brought to the emergency department from the nursing home due to explosive diarrhea. Laboratory studies show leukocytosis, and results from a stool specimen return positive for *Clostridium difficile* toxin genes by polymerase chain reaction. Three days later, one of the nurses who cared for the patient at the nursing home is admitted with diarrhea and is found to have *C difficile* infection. However, the other nurses who also took care of the patient are asymptomatic and do not develop the infection. If all the nurses were similarly exposed to *C difficile*, which of the following is the most likely reason that the asymptomatic nurses did not develop the infection?

- A. Adequate pancreatic enzyme secretion
- B. Intact cell-mediated immunity
- C. Preformed antispore immunoglobulins
- D. Preserved intestinal microbiome
- E. Rapid gastrointestinal transit and expulsion of spores

Submit

A 79-year-old woman is brought to the emergency department from the nursing home due to explosive diarrhea. Laboratory studies show leukocytosis, and results from a stool specimen return positive for *Clostridium difficile* toxin genes by polymerase chain reaction. Three days later, one of the nurses who cared for the patient at the nursing home is admitted with diarrhea and is found to have *C difficile* infection. However, the other nurses who also took care of the patient are asymptomatic and do not develop the infection. If all the nurses were similarly exposed to *C difficile*, which of the following is the most likely reason that the asymptomatic nurses did not develop the infection?

- A. Adequate pancreatic enzyme secretion (0%)
- B. Intact cell-mediated immunity (5%)
- C. Preformed antispore immunoglobulins (5%)
- ✓ D. Preserved intestinal microbiome (84%)
- E. Rapid gastrointestinal transit and expulsion of spores (4%)

Omitted
Correct answer
D

84%
Answered correctly

01 sec
Time Spent

03/18/2020
Last Updated

Explanation

Over 400 types of bacteria inhabit the healthy human gastrointestinal tract as part of the normal **intestinal microbiome**. In healthy humans, these include very few aerobes (eg, *Pseudomonas*), approximately 10% facultative anaerobes (eg, *Escherichia coli, Klebsiella, Lactobacillus, Bacillus*), and a majority of strict anaerobes (eg, *Bacteroides, Fusobacterium, Clostridium*). These intestinal bacteria effectively **suppress overgrowth of *Clostridium difficile*** and other potentially pathogenic bacteria by competing for nutrients and adhesion sites within the gut.

Explanation

Over 400 types of bacteria inhabit the healthy human gastrointestinal tract as part of the normal **intestinal microbiome**. In healthy humans, these include very few aerobes (eg, *Pseudomonas*), approximately 10% facultative anaerobes (eg, *Escherichia coli, Klebsiella, Lactobacillus, Bacillus*), and a majority of strict anaerobes (eg, *Bacteroides, Fusobacterium, Clostridium*). These intestinal bacteria effectively **suppress overgrowth of *Clostridium difficile*** and other potentially pathogenic bacteria by competing for nutrients and adhesion sites within the gut.

Antibiotic therapy is the most important risk factor for *C difficile* infection (CDI) as it can alter the microbiome, leading to a potential overgrowth of pathogenic strains and clinical disease. The organism causes disease by releasing 2 toxins that damage the mucosal lining of the large intestine, leading to diarrhea (toxin A) and necrosis (toxin B) with pseudomembrane formation.

(Choice A) Increased risk of CDI is seen with proton pump inhibitor use, suggesting that gastric acidity may have a protective role. The pancreas secretes protease, amylase and lipase, and trypsinogen, among others; however, there is no association between pancreatic enzyme secretion and CDI.

(Choice B) Cell-mediated immunity is not essential for prevention of CDI, but it is required to eradicate infections with intracellular agents that avoid the humoral (antibody) immune response (eg, *Legionella, Neisseria gonorrhoeae, Listeria monocytogenes*, viruses, *Leishmania*).

(Choice C) Individuals usually develop serum antibodies against *C difficile* toxins, not spores.

(Choice E) Rapid gastrointestinal transit is rarely effective at "washing away" pathogenic diarrhea-causing organisms as they are well-adapted to adhering to the gut mucosa in the setting of voluminous diarrhea.

Educational objective:
In the absence of normal intestinal microbial flora (as may be the case after a course of antibiotics), *Clostridium difficile* can overgrow and produce enterotoxin (toxin A) and cytotoxin (toxin B). Clinical disease resulting from *C difficile* overgrowth can range from transient diarrhea to severe pseudomembranous colitis.

References

- The host immune response to Clostridium difficile infection.

Clostridium difficile and other potentially pathogenic bacteria by competing for nutrients and adhesion sites within the gut.

Antibiotic therapy is the most important risk factor for *C difficile* infection (CDI) as it can alter the microbiome, leading to a potential overgrowth of pathogenic strains and clinical disease. The organism causes disease by releasing 2 toxins that damage the mucosal lining of the large intestine, leading to diarrhea (toxin A) and necrosis (toxin B) with pseudomembrane formation.

(Choice A) Increased risk of CDI is seen with proton pump inhibitor use, suggesting that gastric acidity may have a protective role. The pancreas secretes protease, amylase and lipase, and trypsinogen, among others; however, there is no association between pancreatic enzyme secretion and CDI.

(Choice B) Cell-mediated immunity is not essential for prevention of CDI, but it is required to eradicate infections with intracellular agents that avoid the humoral (antibody) immune response (eg, *Legionella, Neisseria gonorrhoeae, Listeria monocytogenes*, viruses, *Leishmania*).

(Choice C) Individuals usually develop serum antibodies against *C difficile* toxins, not spores.

(Choice E) Rapid gastrointestinal transit is rarely effective at "washing away" pathogenic diarrhea-causing organisms as they are well-adapted to adhering to the gut mucosa in the setting of voluminous diarrhea.

Educational objective:
In the absence of normal intestinal microbial flora (as may be the case after a course of antibiotics), *Clostridium difficile* can overgrow and produce enterotoxin (toxin A) and cytotoxin (toxin B). Clinical disease resulting from *C difficile* overgrowth can range from transient diarrhea to severe pseudomembranous colitis.

References

- The host immune response to Clostridium difficile infection.

Microbiology	Gastrointestinal & Nutrition	Clostridium difficile infection
Subject	System	Topic

Copyright © UWorld. All rights reserved.

A 23-year-old woman comes to the hospital due to fever, chills, dyspnea, and cough for the past several days. She also has sharp right-sided chest pain exacerbated by breathing. Her temperature is 39 C (102 F), blood pressure is 115/70 mm Hg, and pulse is 108/min. On examination, the patient has several needle track marks on both arms. There is a 3/6 holosystolic murmur heard best at the lower sternal border that increases on inspiration. Chest imaging reveals scattered bilateral peripheral lung opacities. HIV testing is negative. This patient's blood cultures are most likely to grow which of the following organisms?

- A. *Candida albicans*
- B. *Eikenella corrodens*
- C. *Klebsiella pneumoniae*
- D. *Nocardia asteroides*
- E. *Peptostreptococcus*
- F. *Staphylococcus aureus*
- G. *Streptococcus gallolyticus* (formerly *S bovis*)
- H. *Streptococcus pneumoniae*
- I. *Viridans group streptococcus*

Submit

A 23-year-old woman comes to the hospital due to fever, chills, dyspnea, and cough for the past several days. She also has sharp right-sided chest pain exacerbated by breathing. Her temperature is 39 C (102 F), blood pressure is 115/70 mm Hg, and pulse is 108/min. On examination, the patient has several needle track marks on both arms. There is a 3/6 holosystolic murmur heard best at the lower sternal border that increases on inspiration. Chest imaging reveals scattered bilateral peripheral lung opacities. HIV testing is negative. This patient's blood cultures are most likely to grow which of the following organisms?

- A. *Candida albicans* (1%)
- B. *Eikenella corrodens* (0%)
- C. *Klebsiella pneumoniae* (1%)
- D. *Nocardia asteroides* (0%)
- E. *Peptostreptococcus* (0%)
- ✓ F. *Staphylococcus aureus* (88%)
- G. *Streptococcus gallolyticus* (formerly *S bovis*) (0%)
- H. *Streptococcus pneumoniae* (1%)
- I. *Viridans group streptococcus* (4%)

Omitted
Correct answer
F

88%
Answered correctly

02 secs
Time Spent

05/18/2020
Last Updated

Explanation

***Staphylococcus* aureus** can cause **right-sided endocarditis** in **intravenous drug users** (IVDUs). In patients other than IVDUs, *S aureus* disseminates from a primary disease process (eg, abscess, infected central line) and moves by hematogenous spread to the endocardium. *S aureus* settles on the valve leaflets due to blood flow turbulence at these sites. *S aureus* can cause perforations in the heart valves, rupture the chordae tendineae, and send **septic emboli** to the lung (with right heart endocarditis) or to the brain and systemic circulation (with left heart endocarditis). This patient with fever is an IVDU with a holosystolic murmur that increases with inspiration (likely tricuspid regurgitation) and multiple lung opacities (likely septic emboli). She likely has *S aureus* endocarditis.

(Choice A) *Candida* endocarditis (rare) is typically a severe manifestation of candidemia, with septic emboli to the brain, extremities, and gastrointestinal tract. Patients who are IVDUs, have prosthetic heart valves, or have indwelling lines are at increased risk of infection.

(Choice B) Culture-negative endocarditis - due to *Bartonella, Coxiella, Mycoplasma, Histoplasma, Chlamydia*, or the HACEK organisms (***H**aemophilus, **A**ctinobacillus, **C**ardiobacterium, **E**ikenella*, and ***K**ingella*), among others - would be much less likely than *S aureus* endocarditis.

(Choices C, D, E, and H) *Streptococcus pneumoniae* and *Klebsiella pneumoniae* typically cause pneumonia; *Klebsiella* can also lead to urinary tract infections. Nocardiosis typically affects the lungs (cavitary lesions), brain (brain abscess), or skin and is seen mostly in immunocompromised patients. *Peptostreptococcus* causes anaerobic infections (dental, cutaneous, intraabdominal).

(Choice G) *Streptococcus gallolyticus* (formerly *S bovis*) is a part of the normal flora of the colon, and bacteremia or endocarditis caused by *S bovis* is associated with colon cancer (~25% of cases).

(Choice I) *Streptococcus viridans* is the most common etiologic agent in subacute bacterial endocarditis (SBE) following dental work. SBE occurs most frequently in patients with a preexisting valvular abnormality (eg, rheumatic heart disease, congenital heart malformations). The presentation is typically subacute (over weeks rather than days).

Educational objective:
Staphylococcus aureus causes acute bacterial endocarditis with rapid onset of symptoms, including shaking chills (rigors), high fever, dyspnea on exertion, and malaise. In intravenous drug users, it can cause right-sided endocarditis with septic embolization into the lungs.

Microbiology	Cardiovascular System	Endocarditis
Subject	System	Topic

aureus settles on the valve leaflets due to blood flow turbulence at these sites. *S aureus* can cause perforations in the heart valves, rupture the chordae tendineae, and send **septic emboli** to the lung (with right heart endocarditis) or to the brain and systemic circulation (with left heart endocarditis). This patient with fever is an IVDU with a holosystolic murmur that increases with inspiration (likely tricuspid regurgitation) and multiple lung opacities (likely septic emboli). She likely has *S aureus* endocarditis.

(Choice A) *Candida* endocarditis (rare) is typically a severe manifestation of candidemia, with septic emboli to the brain, extremities, and gastrointestinal tract. Patients who are IVDUs, have prosthetic heart valves, or have indwelling lines are at increased risk of infection.

(Choice B) Culture-negative endocarditis - due to *Bartonella, Coxiella, Mycoplasma, Histoplasma, Chlamydia*, or the HACEK organisms (***H**aemophilus, **A**ctinobacillus, **C**ardiobacterium, **E**ikenella*, and ***K**ingella*), among others - would be much less likely than *S aureus* endocarditis.

(Choices C, D, E, and H) *Streptococcus pneumoniae* and *Klebsiella pneumoniae* typically cause pneumonia; *Klebsiella* can also lead to urinary tract infections. Nocardiosis typically affects the lungs (cavitary lesions), brain (brain abscess), or skin and is seen mostly in immunocompromised patients. *Peptostreptococcus* causes anaerobic infections (dental, cutaneous, intraabdominal).

(Choice G) *Streptococcus gallolyticus* (formerly *S bovis*) is a part of the normal flora of the colon, and bacteremia or endocarditis caused by *S bovis* is associated with colon cancer (~25% of cases).

(Choice I) *Streptococcus viridans* is the most common etiologic agent in subacute bacterial endocarditis (SBE) following dental work. SBE occurs most frequently in patients with a preexisting valvular abnormality (eg, rheumatic heart disease, congenital heart malformations). The presentation is typically subacute (over weeks rather than days).

Educational objective:
Staphylococcus aureus causes acute bacterial endocarditis with rapid onset of symptoms, including shaking chills (rigors), high fever, dyspnea on exertion, and malaise. In intravenous drug users, it can cause right-sided endocarditis with septic embolization into the lungs.

Microbiology	Cardiovascular System	Endocarditis
Subject	System	Topic

Copyright © UWorld. All rights reserved.

A 32-year-old man is evaluated due to several weeks of watery diarrhea. He has also had intermittent, crampy abdominal pain and has lost 7 kg (15.4 lb) during this period. The patient has a history of HIV and was hospitalized 6 months ago for *Pneumocystis* pneumonia. On physical examination, the patient is afebrile, and the abdomen is soft and nontender with no organomegaly. Stool tests for leukocytes and occult blood are negative. Colonoscopy is performed, and the mucosal biopsy shows an inflammatory infiltrate in the lamina propria and pathogens lining the epithelium, as shown in the exhibit. The organisms have a cystic appearance on modified acid-fast staining. Which of the following is the most likely cause of this patient's condition?

A. *Clostridium difficile*

B. *Cryptosporidium parvum*

C. *Entameba histolytica*

D. Enteropathogenic *Escherichia coli*

E. *Giardia lamblia*

F. Mycobacterium avium complex

G. *Salmonella enteritidis*

Submit

A 32-year-old man is evaluated due to several weeks of watery diarrhea. He has also had intermittent, crampy abdominal pain and has lost 7 kg (15.4 lb) during this period. The patient has a history of HIV and was hospitalized 6 months ago for *Pneumocystis* pneumonia. On physical examination, the patient is afebrile, and the abdomen is soft and nontender with no organomegaly. Stool tests for leukocytes and occult blood are negative. Colonoscopy is performed, and the mucosal biopsy shows an inflammatory infiltrate in the lamina propria and pathogens lining the epithelium, as shown in the exhibit. The organisms have a cystic appearance on modified acid-fast staining. Which of the following is the most likely cause of this patient's condition?

- A. *Clostridium difficile* (3%)
- ✓ B. *Cryptosporidium parvum* (71%)
- C. *Entameba histolytica* (3%)
- D. Enteropathogenic *Escherichia coli* (0%)
- E. *Giardia lamblia* (4%)
- F. Mycobacterium avium complex (15%)
- G. *Salmonella enteritidis* (0%)

Omitted
Correct answer
B

71%
Answered correctly

01 sec
Time Spent

02/24/2020
Last Updated

Explanation

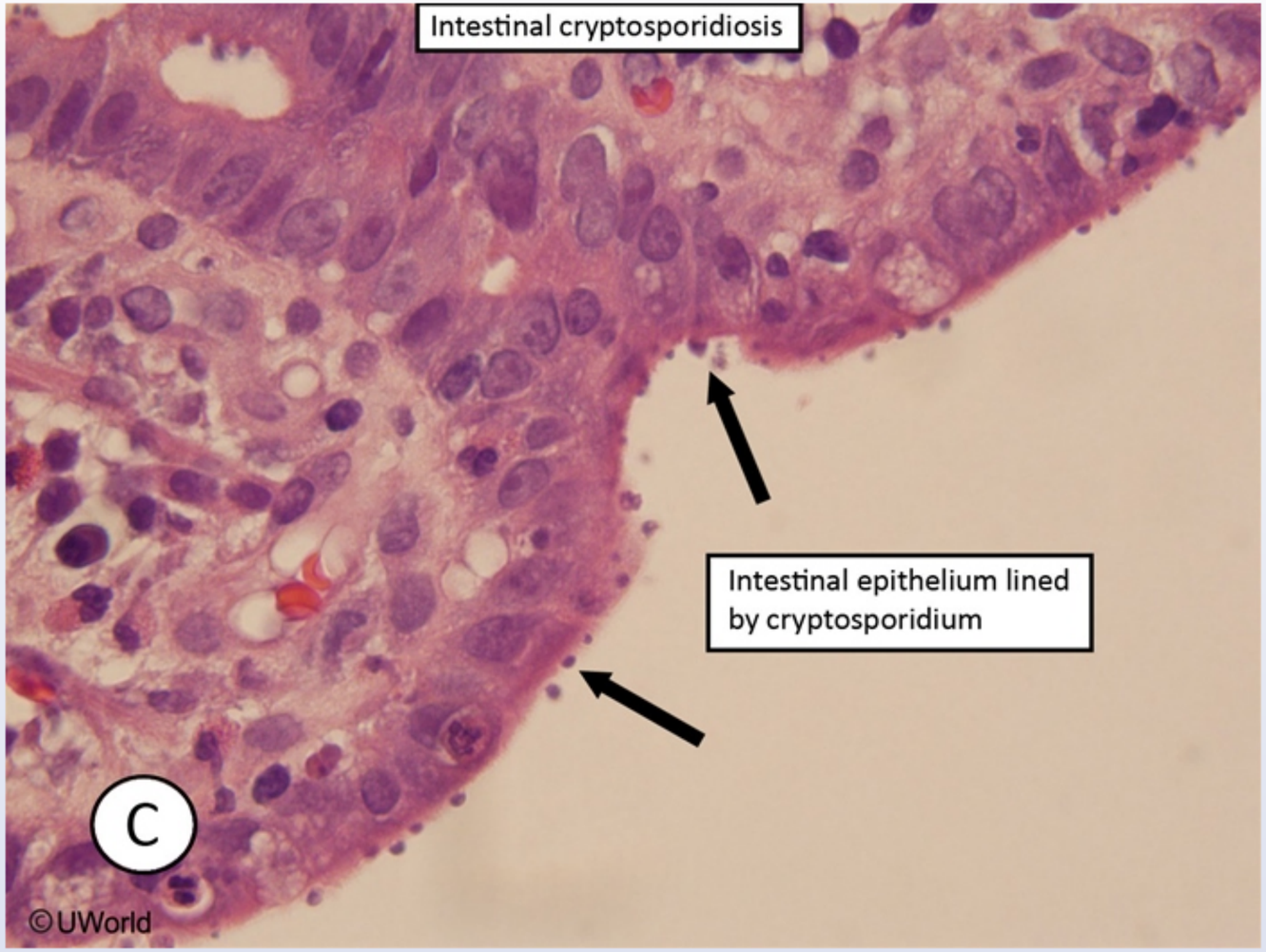

Cryptosporidium is a protozoal organism that is a common cause of infectious diarrhea. Oocytes are ingested in contaminated food or water, travel to the small intestine, and shed sporozoites that attach to the **epithelial cell wall**. Individuals who are otherwise healthy often develop self-limited, **watery (secretory) diarrhea**. However, those with impaired cell-mediated immunity—particularly individuals with **advanced AIDS** (as is

Cryptosporidium is a protozoal organism that is a common cause of infectious diarrhea. Oocytes are ingested in contaminated food or water, travel to the small intestine, and shed sporozoites that attach to the **epithelial cell wall**. Individuals who are otherwise healthy often develop self-limited, **watery (secretory) diarrhea**. However, those with impaired cell-mediated immunity—particularly individuals with **advanced AIDS** (as is likely in this patient with HIV who recently had *Pneumocystis* pneumonia)—are at risk for life-threatening diarrhea with fluid loss of >20 L per day.

Standard ova and parasite stool tests usually cannot detect the organism, and fecal leukocytes/occult blood tests are generally negative (because the pathogen does not cause inflammatory diarrhea). However, the diagnosis can often be made by modified **acid-fast stain** of the stool, which usually reveals **cystic organisms**. Histopathology generally shows **villous blunting**, an inflammatory infiltrate in the lamina propria, and **basophilic *Cryptosporidium* cysts** on the brush border of the mucosal surface.

(Choice A) *Clostridium difficile* is a gram-positive, spore-forming bacterium that causes toxin-mediated inflammatory colitis (usually with fecal leukocytes/blood). It is not acid-fast or cystic.

(Choice C) *Entameba histolytica* is an ameba that causes dysentery (bloody diarrhea). Histopathology generally reveals flask-shaped colonic ulcers with "foamy" trophozoites that resemble macrophages.

(Choice D) Enteropathogenic *Escherichia coli* attaches to and effaces the small bowel epithelium, leading to watery, noninflammatory (no blood or leukocytes) diarrhea. However, this pathogen is a gram-negative rod, not an acid-fast cyst.

(Choice E) *Giardia lamblia* is a protozoal organism that classically causes foul-smelling, greasy diarrhea and excessive flatulence after consumption of contaminated water. Stool microscopy generally shows oval/ellipsoid cysts or trophozoites; they are not acid-fast.

(Choice F) Mycobacterium avium complex is a common opportunistic infection in patients with advanced AIDS (CD4 count <50/mm^3) and often presents with diarrhea and weight loss. It is marked by acid-fast bacteria within macrophages.

(Choice G) *Salmonella enteritis* is a common food-borne infection and usually presents with acute, self-limited diarrhea, vomiting, fever, and abdominal cramping. It is a gram-negative bacillus, not an acid-fast cyst.

Educational objective:
Cryptosporidium is a common cause of self-limited diarrhea in immunocompetent hosts, but may cause life-threatening diarrhea in immunocompromised patients (eg, advanced AIDS). Diagnosis is usually made when oocysts are visualized with modified acid-fast stain in stool or biopsy (oocysts lining the brush-border).

usually reveals **cystic organisms**. Histopathology generally shows **villous blunting**, an inflammatory infiltrate in the lamina propria, and **basophilic *Cryptosporidium* cysts** on the brush border of the mucosal surface.

(Choice A) *Clostridium difficile* is a gram-positive, spore-forming bacterium that causes toxin-mediated inflammatory colitis (usually with fecal leukocytes/blood). It is not acid-fast or cystic.

(Choice C) *Entameba histolytica* is an ameba that causes dysentery (bloody diarrhea). Histopathology generally reveals flask-shaped colonic ulcers with "foamy" trophozoites that resemble macrophages.

(Choice D) Enteropathogenic *Escherichia coli* attaches to and effaces the small bowel epithelium, leading to watery, noninflammatory (no blood or leukocytes) diarrhea. However, this pathogen is a gram-negative rod, not an acid-fast cyst.

(Choice E) *Giardia lamblia* is a protozoal organism that classically causes foul-smelling, greasy diarrhea and excessive flatulence after consumption of contaminated water. Stool microscopy generally shows oval/ellipsoid cysts or trophozoites; they are not acid-fast.

(Choice F) Mycobacterium avium complex is a common opportunistic infection in patients with advanced AIDS (CD4 count <50/mm^3) and often presents with diarrhea and weight loss. It is marked by acid-fast bacteria within macrophages.

(Choice G) *Salmonella enteritis* is a common food-borne infection and usually presents with acute, self-limited diarrhea, vomiting, fever, and abdominal cramping. It is a gram-negative bacillus, not an acid-fast cyst.

Educational objective:
Cryptosporidium is a common cause of self-limited diarrhea in immunocompetent hosts, but may cause life-threatening diarrhea in immunocompromised patients (eg, advanced AIDS). Diagnosis is usually made when oocysts are visualized with modified acid-fast stain in stool or biopsy (oocysts lining the brush-border).

Microbiology	Gastrointestinal & Nutrition	Cryptosporidiosis
Subject	System	Topic

Copyright © UWorld. All rights reserved.

Settings

1 2 3 4 5 6 7 8 9 10 11 12 13 14 15 16 17 18 19 20 21 22 23 24 25 26 27 28 29 30

Item 8 of 38
Question Id: 7642

Mark | Previous | Next | Full Screen | Tutorial | Lab Values | Notes | Calculator | Reverse Color | Text Zoom | Settings

Exhibit Display

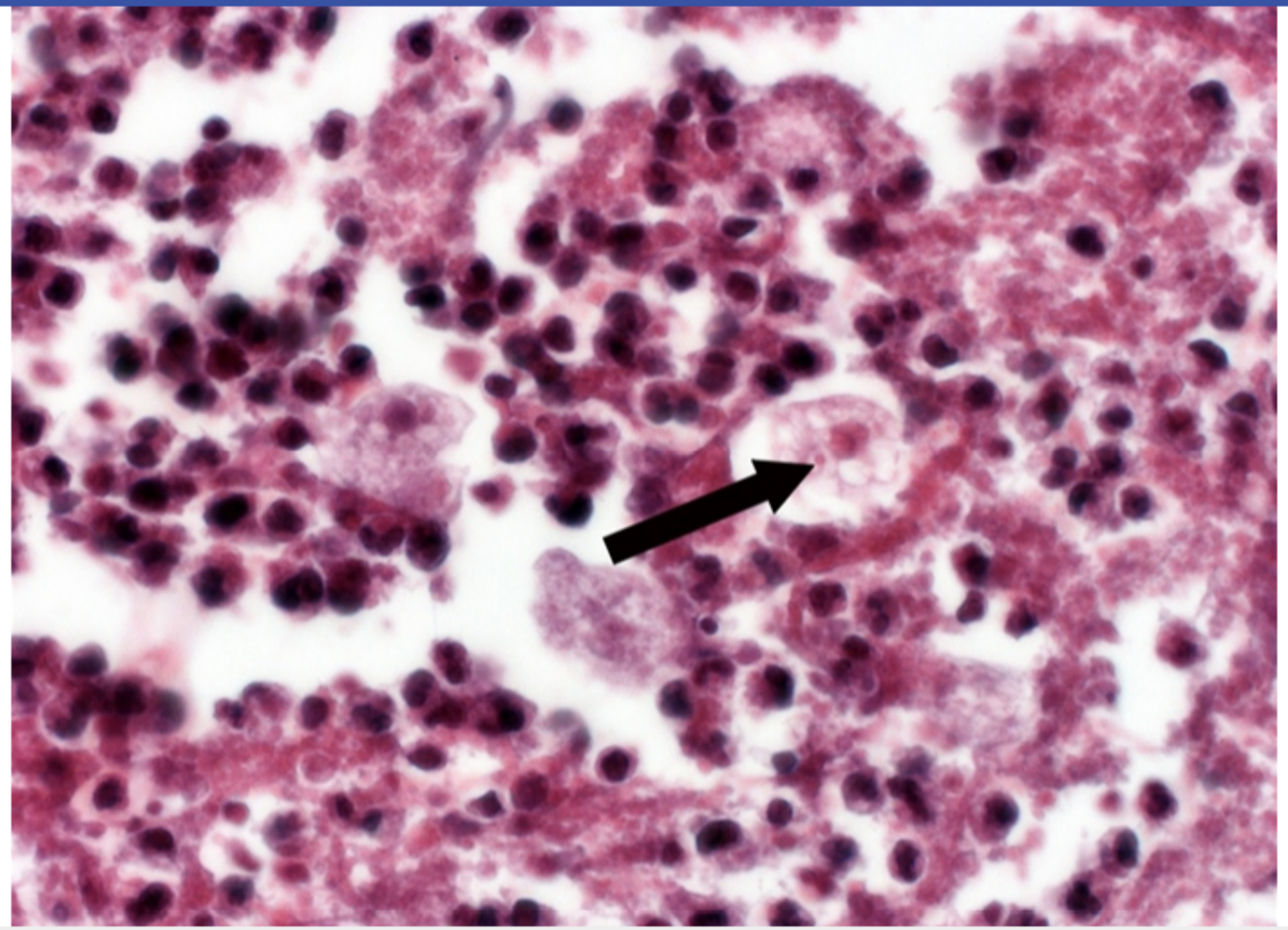

Zoom In | Zoom Out | Reset | Add To New Card | Existing Card

Block Time Remaining: 00:00:17
TUTOR

6 | Feedback | Suspend | End Block

Settings

1 2 3 4 5 6 7 8 9 10 11 12 13 14 15 16 17 18 19 20 21 22 23 24 25 26 27 28 29 30

Item 8 of 38
Question Id: 7642

Mark | Previous | Next | Full Screen | Tutorial | Lab Values | Notes | Calculator | Reverse Color | Text Zoom | Settings

the pathogen does not cause inflammatory diarrhea). However, the diagnosis can often be made by modified **acid-fast stain** of the stool, which usually reveals **cystic organisms**. Histopathology generally shows **villous blunting**, an inflammatory infiltrate in the lamina propria, and

Exhibit Display

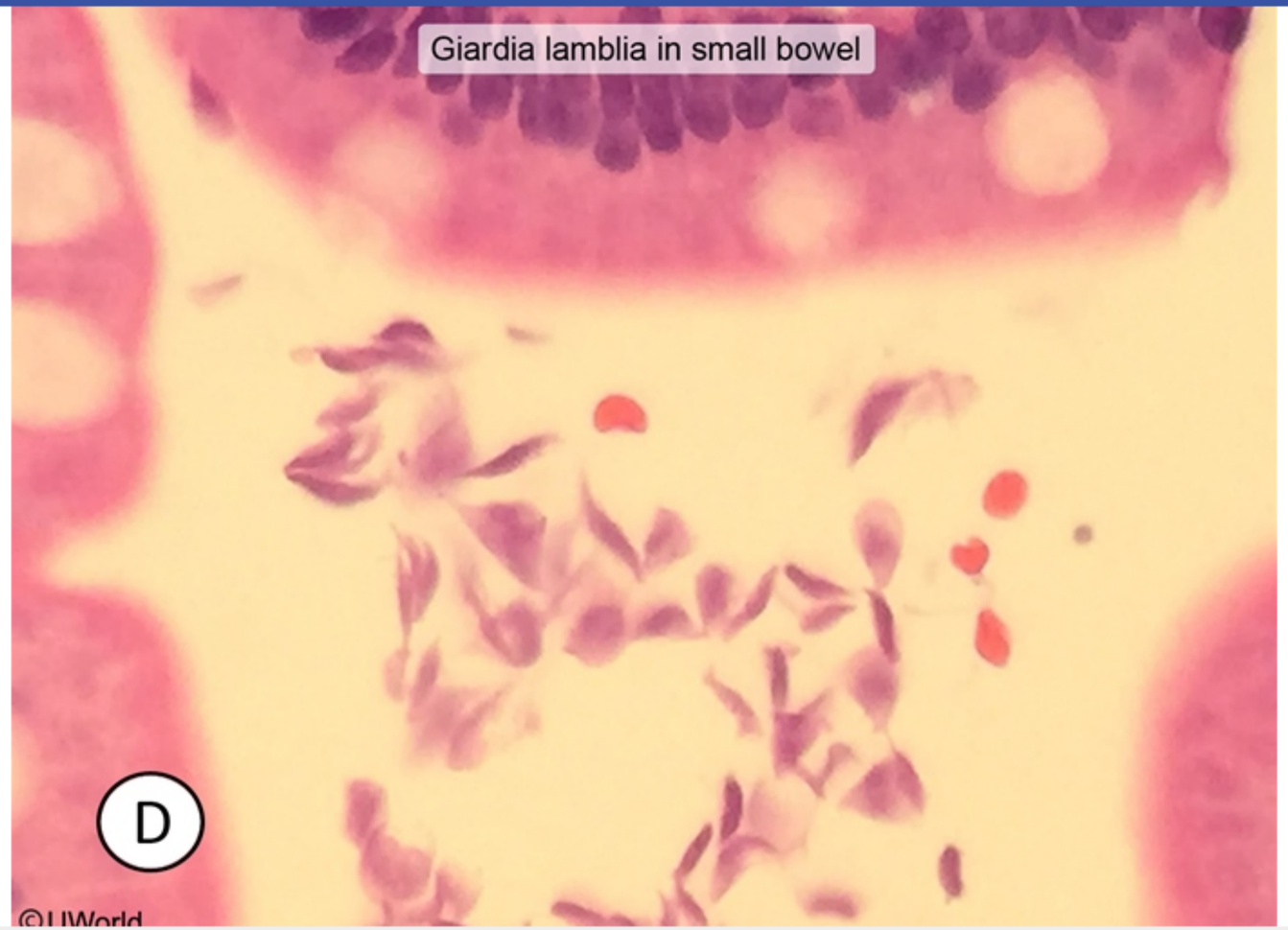

Zoom In | Zoom Out | Reset | Add To New Card | Existing Card

Block Time Remaining: 00:00:17
TUTOR

6 | Feedback | Suspend | End Block

Settings

1 2 3 4 5 6 7 8 9 10 11 12 13 14 15 16 17 18 19 20 21 22 23 24 25 26 27 28 29 30

Item 8 of 38
Question Id: 7642

Mark | Previous | Next | Full Screen | Tutorial | Lab Values | Notes | Calculator | Reverse Color | Text Zoom | Settings

Exhibit Display

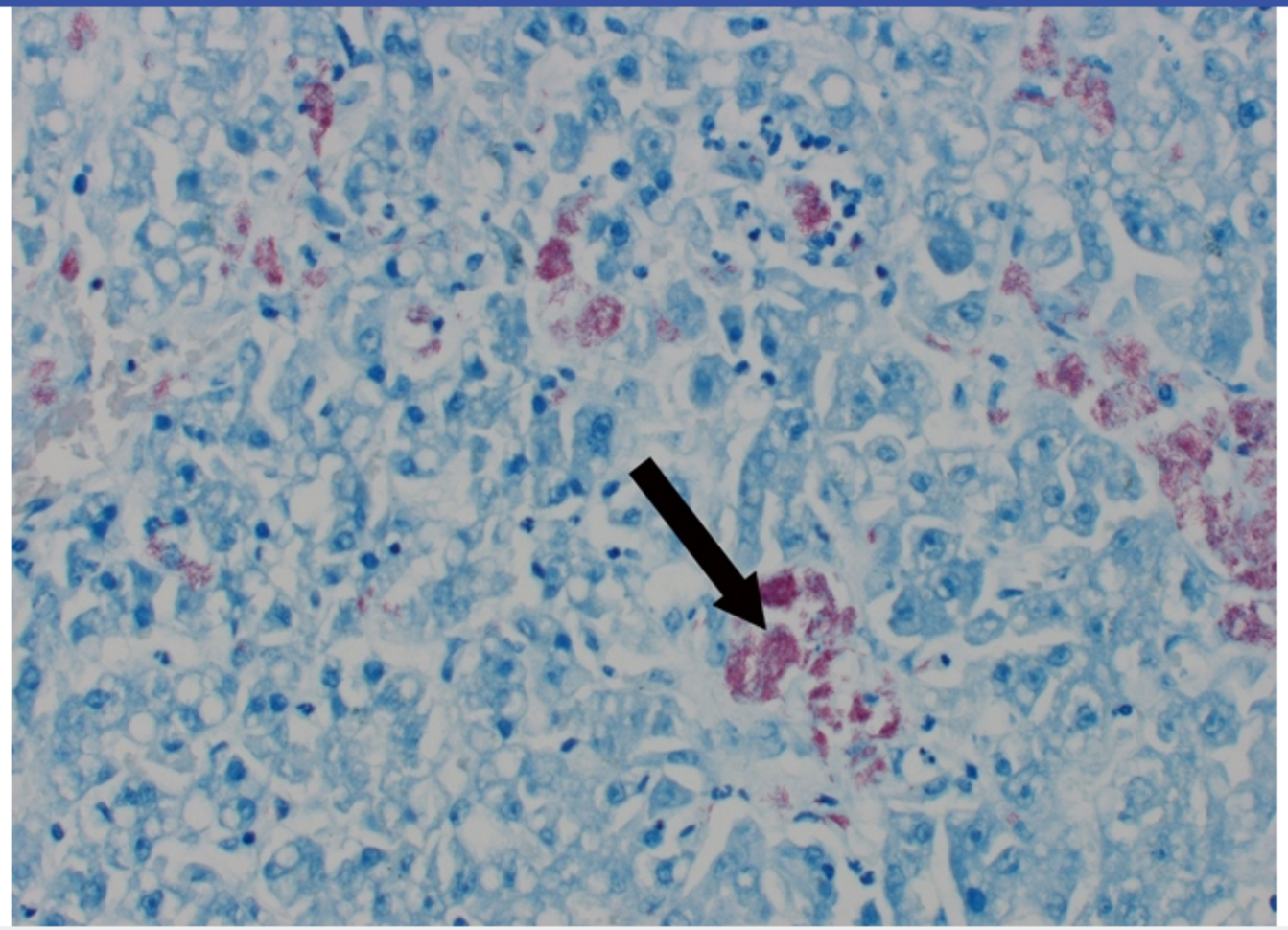

Zoom In | Zoom Out | Reset | Add To New Card | Existing Card

Block Time Remaining: 00:00:17
TUTOR

6 | Feedback | Suspend | End Block

A 6-year-old previously healthy girl is brought to the emergency department due to a day of fever, abdominal pain, and diarrhea. The symptoms began abruptly with high fever and cramping, periumbilical abdominal pain and were quickly followed by low-volume diarrhea mixed with blood and mucus. The patient has had no sick contacts and has not traveled recently; the family had dinner at a buffet restaurant 3 days ago. Temperature is 38.9 C (102 F). Physical examination reveals mild diffuse abdominal tenderness with no guarding or rebound tenderness. Bowel sounds are hyperactive. Stool occult blood testing is positive, and there are numerous leukocytes in the stool. Culture of the stool yields gram-negative, oxidase-positive, curved rods. Which of the following is the most likely pathogen responsible for this patient's symptoms?

- A. *Campylobacter jejuni*
- B. *Escherichia coli*
- C. *Salmonella enterica*
- D. *Shigella flexneri*
- E. *Vibrio cholerae*

Submit

A 6-year-old previously healthy girl is brought to the emergency department due to a day of fever, abdominal pain, and diarrhea. The symptoms began abruptly with high fever and cramping, periumbilical abdominal pain and were quickly followed by low-volume diarrhea mixed with blood and mucus. The patient has had no sick contacts and has not traveled recently; the family had dinner at a buffet restaurant 3 days ago. Temperature is 38.9 C (102 F). Physical examination reveals mild diffuse abdominal tenderness with no guarding or rebound tenderness. Bowel sounds are hyperactive. Stool occult blood testing is positive, and there are numerous leukocytes in the stool. Culture of the stool yields gram-negative, oxidase-positive, curved rods. Which of the following is the most likely pathogen responsible for this patient's symptoms?

- ✓ A. *Campylobacter jejuni* (81%)
- B. *Escherichia coli* (3%)
- C. *Salmonella enterica* (4%)
- D. *Shigella flexneri* (5%)
- E. *Vibrio cholerae* (5%)

Omitted
Correct answer
A

81%
Answered correctly

02 secs
Time Spent

02/15/2020
Last Updated

Explanation

Campylobacter jejuni	
	• Motile, curved, gram-negative rod

Campylobacter jejuni	
Epidemiology	• Motile, curved, gram-negative rod • Leading cause of **foodborne gastroenteritis** • Transmission: contaminated food (undercooked **poultry**) & pets (dogs)
Manifestations	• Fever, abdominal pain, **watery diarrhea** ± bloody diarrhea • Self-limited in most cases; lasts ~7 days
Complications	• **Guillain-Barré** syndrome (cross-reacting antibody to myelin gangliosides)

Campylobacter jejuni is a motile, **oxidase-positive, curved, gram-negative rod** that is a leading cause of bacterial gastroenteritis in the United States. This pathogen resides in the gastrointestinal tract of a wide range of mammals and is transmitted via the fecal-oral route. Most cases arise when humans ingest contaminated food, particularly **undercooked poultry** or unpasteurized milk, but a minority of infections is caused by close contact with domesticated animals (eg, dogs, farm animals).

C jejuni is enteroinvasive and typically causes fever, abdominal pain, and **diarrhea** that may or may not be bloody. Stool studies usually reveal inflammation (blood, leukocytes); culture of the stool (enriched media at 42 C [107.6 F] and microaerophilic conditions) is diagnostic. Most cases are self-limited and resolve with supportive treatment within 5 days.

(Choice B) *Escherichia coli* causes many forms of gastroenteritis, including enterotoxin-mediated watery diarrhea (enterotoxigenic), Shiga toxin–mediated hemorrhagic colitis (enterohemorrhagic), and invasive colitis (enteroinvasive). Although this pathogen is a gram-negative enteric rod, it is oxidase-negative and not typically described as curved.

(Choice C) Non-typhoidal *Salmonella* (*S enterica*) is a common cause of bacterial gastroenteritis. This enteroinvasive pathogen frequently causes self-limited abdominal pain, fever, and watery diarrhea (bloody diarrhea is less common but can occur). However, *Salmonella* is oxidase-negative and not typically described as curved.

(Choice D) *Shigella* is a highly virulent bacterium that is often transmitted via the fecal-oral route in day care centers or other areas of communal habitation. It causes inflammatory colitis with fever; abdominal pain; and mucoid, bloody, and/or watery diarrhea. Shiga toxin, which irreversibly

Campylobacter jejuni is a motile, **oxidase-positive, curved, gram-negative rod** that is a leading cause of bacterial gastroenteritis in the United States. This pathogen resides in the gastrointestinal tract of a wide range of mammals and is transmitted via the fecal-oral route. Most cases arise when humans ingest contaminated food, particularly **undercooked poultry** or unpasteurized milk, but a minority of infections is caused by close contact with domesticated animals (eg, dogs, farm animals).

C jejuni is enteroinvasive and typically causes fever, abdominal pain, and **diarrhea** that may or may not be bloody. Stool studies usually reveal inflammation (blood, leukocytes); culture of the stool (enriched media at 42 C [107.6 F] and microaerophilic conditions) is diagnostic. Most cases are self-limited and resolve with supportive treatment within 5 days.

(Choice B) *Escherichia coli* causes many forms of gastroenteritis, including enterotoxin-mediated watery diarrhea (enterotoxigenic), Shiga toxin–mediated hemorrhagic colitis (enterohemorrhagic), and invasive colitis (enteroinvasive). Although this pathogen is a gram-negative enteric rod, it is oxidase-negative and not typically described as curved.

(Choice C) Non-typhoidal *Salmonella* (*S enterica*) is a common cause of bacterial gastroenteritis. This enteroinvasive pathogen frequently causes self-limited abdominal pain, fever, and watery diarrhea (bloody diarrhea is less common but can occur). However, *Salmonella* is oxidase-negative and not typically described as curved.

(Choice D) *Shigella* is a highly virulent bacterium that is often transmitted via the fecal-oral route in day care centers or other areas of communal habituation. It causes inflammatory colitis with fever; abdominal pain; and mucoid, bloody, and/or watery diarrhea. Shiga toxin, which irreversibly inhibits host cell protein synthesis, is a major virulence factor. However, *Shigella* is oxidase-negative and is not typically described as curved.

(Choice E) *Vibrio cholerae* is also a curved, oxidase-positive, gram-negative enteric rod and can therefore occasionally be misidentified as a *Campylobacter* species. However, *V cholerae* causes massive watery diarrhea (due to cholera toxin) that is noninflammatory (no fecal leukocytes or erythrocytes).

Educational objective:
Campylobacter jejuni is an oxidase-positive, curved, gram-negative rod that is a leading cause of gastroenteritis. The pathogen is a zoonotic organism most commonly contracted by consuming contaminated, undercooked poultry. Cases are marked by fever, abdominal pain, and diarrhea that may be bloody.

C jejuni is enteroinvasive and typically causes fever, abdominal pain, and **diarrhea** that may or may not be bloody. Stool studies usually reveal inflammation (blood, leukocytes); culture of the stool (enriched media at 42 C [107.6 F] and microaerophilic conditions) is diagnostic. Most cases are self-limited and resolve with supportive treatment within 5 days.

(Choice B) *Escherichia coli* causes many forms of gastroenteritis, including enterotoxin-mediated watery diarrhea (enterotoxigenic), Shiga toxin–mediated hemorrhagic colitis (enterohemorrhagic), and invasive colitis (enteroinvasive). Although this pathogen is a gram-negative enteric rod, it is oxidase-negative and not typically described as curved.

(Choice C) Non-typhoidal *Salmonella* (*S enterica*) is a common cause of bacterial gastroenteritis. This enteroinvasive pathogen frequently causes self-limited abdominal pain, fever, and watery diarrhea (bloody diarrhea is less common but can occur). However, *Salmonella* is oxidase-negative and not typically described as curved.

(Choice D) *Shigella* is a highly virulent bacterium that is often transmitted via the fecal-oral route in day care centers or other areas of communal habituation. It causes inflammatory colitis with fever; abdominal pain; and mucoid, bloody, and/or watery diarrhea. Shiga toxin, which irreversibly inhibits host cell protein synthesis, is a major virulence factor. However, *Shigella* is oxidase-negative and is not typically described as curved.

(Choice E) *Vibrio cholerae* is also a curved, oxidase-positive, gram-negative enteric rod and can therefore occasionally be misidentified as a *Campylobacter* species. However, *V cholerae* causes massive watery diarrhea (due to cholera toxin) that is noninflammatory (no fecal leukocytes or erythrocytes).

Educational objective:
Campylobacter jejuni is an oxidase-positive, curved, gram-negative rod that is a leading cause of gastroenteritis. The pathogen is a zoonotic organism most commonly contracted by consuming contaminated, undercooked poultry. Cases are marked by fever, abdominal pain, and diarrhea that may be bloody.

Microbiology	Gastrointestinal & Nutrition	Acute diarrhea
Subject	System	Topic

Copyright © UWorld. All rights reserved.

C jejuni is enteroinvasive and typically causes fever, abdominal pain, and **diarrhea** that may or may not be bloody. Stool studies usually reveal inflammation (blood, leukocytes); culture of the stool (enriched media at 42 C [107.6 F] and microaerophilic conditions) is diagnostic. Most cases are self-limited and resolve with supportive treatment within 5 days.

(Choice B) *Escherichia coli* causes many forms of gastroenteritis, including enterotoxin-mediated watery diarrhea (enterotoxigenic), Shiga toxin–mediated hemorrhagic colitis (enterohemorrhagic), and invasive colitis (enteroinvasive). Although this pathogen is a gram-negative enteric rod, it is oxidase-negative and not typically described as curved.

(Choice C) Non-typhoidal *Salmonella* (*S enterica*) is a common cause of bacterial gastroenteritis. This enteroinvasive pathogen frequently causes self-limited abdominal pain, fever, and watery diarrhea (bloody diarrhea is less common but can occur). However, *Salmonella* is oxidase-negative and not typically described as curved.

(Choice D) *Shigella* is a highly virulent bacterium that is often transmitted via the fecal-oral route in day care centers or other areas of communal habituation. It causes inflammatory colitis with fever; abdominal pain; and mucoid, bloody, and/or watery diarrhea. Shiga toxin, which irreversibly inhibits host cell protein synthesis, is a major virulence factor. However, *Shigella* is oxidase-negative and is not typically described as curved.

(Choice E) *Vibrio cholerae* is also a curved, oxidase-positive, gram-negative enteric rod and can therefore occasionally be misidentified as a *Campylobacter* species. However, *V cholerae* causes massive watery diarrhea (due to cholera toxin) that is noninflammatory (no fecal leukocytes or erythrocytes).

Educational objective:
Campylobacter jejuni is an oxidase-positive, curved, gram-negative rod that is a leading cause of gastroenteritis. The pathogen is a zoonotic organism most commonly contracted by consuming contaminated, undercooked poultry. Cases are marked by fever, abdominal pain, and diarrhea that may be bloody.

Microbiology	Gastrointestinal & Nutrition	Acute diarrhea
Subject	System	Topic

Copyright © UWorld. All rights reserved.

A 54-year-old man comes to the emergency department after vomiting blood. He has also had melena, fatigue, and lethargy over the last 24 hours. The patient emigrated from sub-Saharan Africa 20 years ago and occasionally returns to visit friends and family. Temperature is 37.5 C (99.5 F), blood pressure is 90/60 mm Hg, and pulse is 115/min. Abdominal palpation reveals an enlarged liver and a spleen tip below the level of the umbilicus. Laboratory results are as follows:

Complete blood count

Hemoglobin	5.2 g/dL
Platelets	75,000/mm^3
Leukocytes	8,000/mm^3
Neutrophils	79%
Eosinophils	15%
Lymphocytes	6%

Upper endoscopy reveals bleeding esophageal varices. Which of the following is the most likely underlying cause of this patient's symptoms?

A. Cysticercosis
B. Hookworm infection
C. Malaria
D. Schistosomiasis
E. Toxoplasmosis

hours. The patient emigrated from sub-Saharan Africa 20 years ago and occasionally returns to visit friends and family. Temperature is 37.5 C (99.5 F), blood pressure is 90/60 mm Hg, and pulse is 115/min. Abdominal palpation reveals an enlarged liver and a spleen tip below the level of the umbilicus. Laboratory results are as follows:

Complete blood count

Hemoglobin	5.2 g/dL
Platelets	75,000/mm^3
Leukocytes	8,000/mm^3
Neutrophils	79%
Eosinophils	15%
Lymphocytes	6%

Upper endoscopy reveals bleeding esophageal varices. Which of the following is the most likely underlying cause of this patient's symptoms?

A. Cysticercosis
B. Hookworm infection
C. Malaria
D. Schistosomiasis
E. Toxoplasmosis

Submit

hours. The patient emigrated from sub-Saharan Africa 20 years ago and occasionally returns to visit friends and family. Temperature is 37.5 C (99.5 F), blood pressure is 90/60 mm Hg, and pulse is 115/min. Abdominal palpation reveals an enlarged liver and a spleen tip below the level of the umbilicus. Laboratory results are as follows:

Complete blood count

Hemoglobin	5.2 g/dL
Platelets	75,000/mm^3
Leukocytes	8,000/mm^3
Neutrophils	79%
Eosinophils	15%
Lymphocytes	6%

Upper endoscopy reveals bleeding esophageal varices. Which of the following is the most likely underlying cause of this patient's symptoms?

A. Cysticercosis (5%)
B. Hookworm infection (12%)
C. Malaria (18%)
✓ D. Schistosomiasis (62%)
E. Toxoplasmosis (0%)

Omitted
Correct answer

62%
Answered correctly

05 secs
Time Spent

02/05/2020
Last Updated

Explanation

Schistosomiasis		
***Schistosoma* species**	**Location**	**Symptoms**
S haematobium	• North Africa • Sub-Saharan Africa • Middle East	**Urinary schistosomiasis** • Terminal hematuria, dysuria & frequent urination • Hydronephrosis, pyelonephritis & squamous cell carcinoma of the bladder
S mansoni	• Sub-Saharan Africa • Middle East • South America • Caribbean	**Intestinal schistosomiasis** • Diarrhea & abdominal pain • Intestinal ulceration → iron deficiency anemia **Hepatic schistosomiasis** • Hepatomegaly, splenomegaly • Periportal fibrosis & subsequent portal hypertension
S japonicum	• Asia, particularly China • Philippines • Japan	

Esophageal varices and splenomegaly are signs of **portal hypertension**, which usually indicates underlying hepatic fibrosis. Although chronic viral hepatitis and alcohol abuse are the leading causes of hepatic fibrosis in the United States, this patient's immigration/travel history and eosinophilia raise suspicion for **hepatosplenic schistosomiasis**, a parasitic blood fluke infection seen primarily in rural parts of **sub-Saharan Africa** and East Asia.

Exposure to *Schistosoma* occurs when humans swim in freshwater contaminated by infected snails (the intermediate host). Cercariae penetrate human skin and migrate to the liver, where they mature to adult worms. Adult worms then spread through the **portal circulation** to the mesenteric venules or venous plexus of the bladder. Here, they release eggs into host tissue that are excreted in the feces or urine.

Although many patients with schistosomiasis are asymptomatic, chronic exposure to *Schistosoma* eggs can activate hepatic stellate cells, leading to collagen deposition in periportal spaces and progressive **periportal fibrosis**. Occlusion of periportal veins eventually blocks venous outflow

	• Japan	

Esophageal varices and splenomegaly are signs of **portal hypertension**, which usually indicates underlying hepatic fibrosis. Although chronic viral hepatitis and alcohol abuse are the leading causes of hepatic fibrosis in the United States, this patient's immigration/travel history and eosinophilia raise suspicion for **hepatosplenic schistosomiasis**, a parasitic blood fluke infection seen primarily in rural parts of **sub-Saharan Africa** and East Asia.

Exposure to *Schistosoma* occurs when humans swim in freshwater contaminated by infected snails (the intermediate host). Cercariae penetrate human skin and migrate to the liver, where they mature to adult worms. Adult worms then spread through the **portal circulation** to the mesenteric venules or venous plexus of the bladder. Here, they release eggs into host tissue that are excreted in the feces or urine.

Although many patients with schistosomiasis are asymptomatic, chronic exposure to *Schistosoma* eggs can activate hepatic stellate cells, leading to collagen deposition in periportal spaces and progressive **periportal fibrosis**. Occlusion of periportal veins eventually blocks venous outflow from abdominal organs, leading to **congestive splenomegaly** and **gastroesophageal varices**. Patients frequently have anemia from intestinal/variceal bleeding, thrombocytopenia from splenic trapping of platelets, and **eosinophilia** in response to adult worms.

(Choice A) Cysticercosis is caused by ingestion of *Taenia solium* eggs from contaminated pork. Although initial infections are usually asymptomatic, patients may develop seizures years or decades later due to calcified granulomas at the site of previous brain infection. Muscle and subcutaneous tissue can also be involved, but the liver and hepatic venous system is generally not affected.

(Choice B) Hookworm infection is a common cause of chronic, iron-deficiency anemia and eosinophilia, but this organism does not invade the liver or portal venous system; therefore, gastric varices and hepatosplenomegaly would be atypical.

(Choice C) Malaria is common in patients who return to endemic areas (eg, sub-Saharan Africa) after being away (due to waning partial immunity). Although hepatosplenomegaly and anemia are common, most patients are acutely ill (eg, fever, chills, malaise), and portal hypertension and eosinophilia are generally not present.

(Choice E) Toxoplasmosis is most common in patients with AIDS. It usually presents with meningoencephalitis (eg, confusion, headache, vomiting). Upper gastrointestinal bleeding from esophageal varices and eosinophilia would be atypical.

Educational objective:

Schistosomiasis, a parasitic blood fluke infection, is common in rural portions of sub-Saharan Africa. Initial infection is often asymptomatic, but

venules or venous plexus of the bladder. Here, they release eggs into host tissue that are excreted in the feces or urine.

Although many patients with schistosomiasis are asymptomatic, chronic exposure to *Schistosoma* eggs can activate hepatic stellate cells, leading to collagen deposition in periportal spaces and progressive **periportal fibrosis**. Occlusion of periportal veins eventually blocks venous outflow from abdominal organs, leading to **congestive splenomegaly** and **gastroesophageal varices**. Patients frequently have anemia from intestinal/variceal bleeding, thrombocytopenia from splenic trapping of platelets, and **eosinophilia** in response to adult worms.

(Choice A) Cysticercosis is caused by ingestion of *Taenia solium* eggs from contaminated pork. Although initial infections are usually asymptomatic, patients may develop seizures years or decades later due to calcified granulomas at the site of previous brain infection. Muscle and subcutaneous tissue can also be involved, but the liver and hepatic venous system is generally not affected.

(Choice B) Hookworm infection is a common cause of chronic, iron-deficiency anemia and eosinophilia, but this organism does not invade the liver or portal venous system; therefore, gastric varices and hepatosplenomegaly would be atypical.

(Choice C) Malaria is common in patients who return to endemic areas (eg, sub-Saharan Africa) after being away (due to waning partial immunity). Although hepatosplenomegaly and anemia are common, most patients are acutely ill (eg, fever, chills, malaise), and portal hypertension and eosinophilia are generally not present.

(Choice E) Toxoplasmosis is most common in patients with AIDS. It usually presents with meningoencephalitis (eg, confusion, headache, vomiting). Upper gastrointestinal bleeding from esophageal varices and eosinophilia would be atypical.

Educational objective:
Schistosomiasis, a parasitic blood fluke infection, is common in rural portions of sub-Saharan Africa. Initial infection is often asymptomatic, but some patients develop chronic hepatosplenic (eg, portal hypertension, hepatosplenomegaly, esophageal varices) or urinary (eg, bladder cancer) complications years or decades later. The presence of eosinophilia is an important diagnostic clue.

Microbiology	Gastrointestinal & Nutrition	Schistosomiasis
Subject	System	Topic

Copyright © UWorld. All rights reserved.

A 67-year-old man comes to the emergency department with low-grade fevers and fatigue. He has no history of heart disease. His temperature is 38.4 C (101.1 F), blood pressure is 117/76 mm Hg, pulse is 82/min, and respirations are 14/min. On examination, there is a diastolic murmur at the left sternal border. He has nontender erythematous macules on his hands and feet. Blood cultures show gram-positive cocci that are catalase-negative and able to grow in hypertonic (6.5%) saline and bile. This patient's medical history is most likely to include which of the following procedures within the past month?

A. Cystoscopy

B. Dental extraction

C. Nasal polypectomy

D. Sinus drainage

E. Skin biopsy

Submit

A 67-year-old man comes to the emergency department with low-grade fevers and fatigue. He has no history of heart disease. His temperature is 38.4 C (101.1 F), blood pressure is 117/76 mm Hg, pulse is 82/min, and respirations are 14/min. On examination, there is a diastolic murmur at the left sternal border. He has nontender erythematous macules on his hands and feet. Blood cultures show gram-positive cocci that are catalase-negative and able to grow in hypertonic (6.5%) saline and bile. This patient's medical history is most likely to include which of the following procedures within the past month?

- ✓ A. Cystoscopy (39%)
- B. Dental extraction (52%)
- C. Nasal polypectomy (2%)
- D. Sinus drainage (2%)
- E. Skin biopsy (2%)

Omitted
Correct answer
A

39%
Answered correctly

02 secs
Time Spent

06/30/2020
Last Updated

Explanation

Microbiological laboratory identification of streptococci

Gram-positive cocci —Catalase-positive→ Staphylococci

Catalase-negative

Microbiological laboratory identification of streptococci

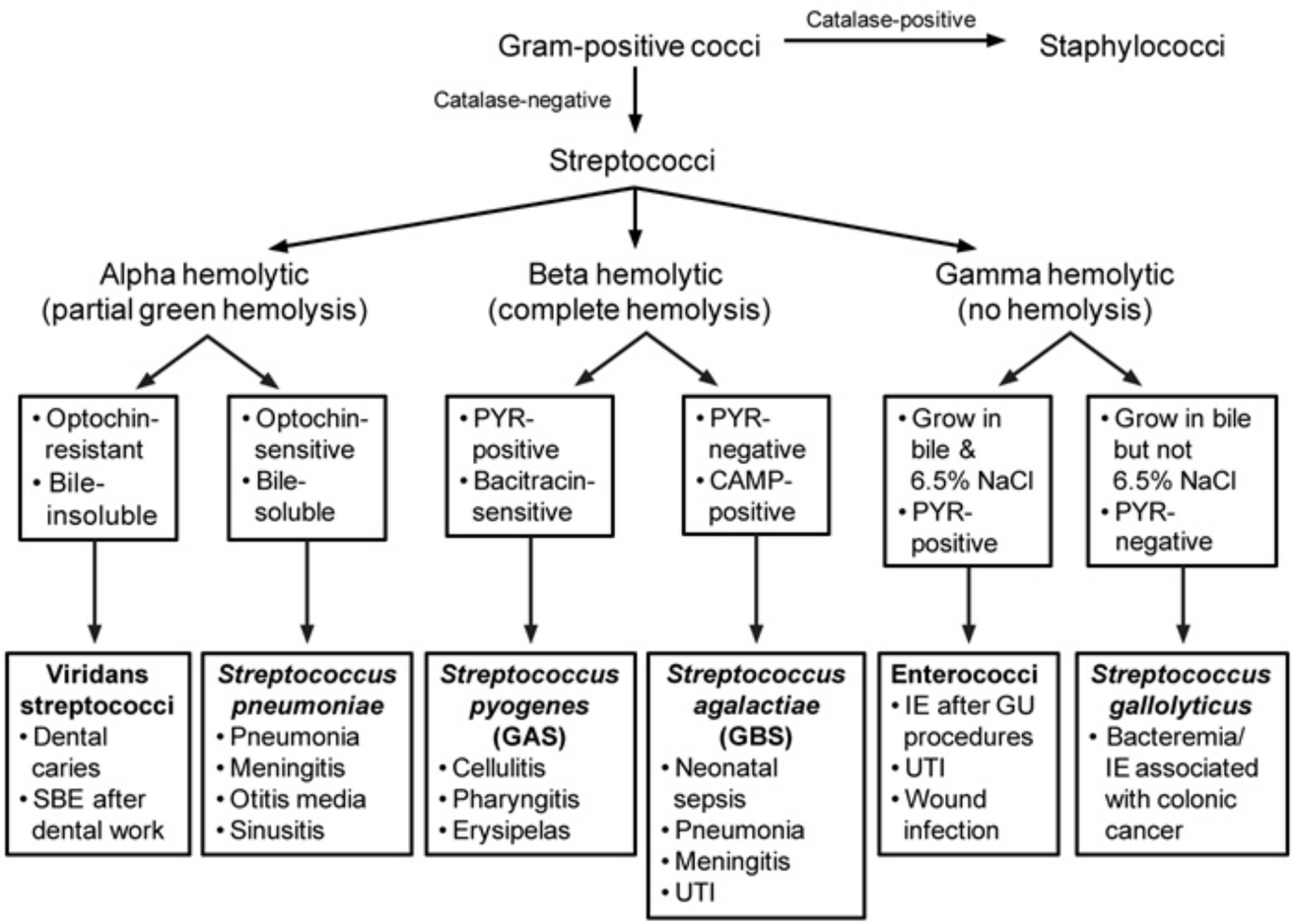

A number of species were formally reclassified from the genus *Streptococcus* to the genus *Enterococcus*, but enterococci are included here under streptococci for simplicity.

CAMP = Christie, Atkins, and Munch-Petersen test; **GAS** = group A streptococci; **GBS** = group B streptococci; **GU** = genitourinary; **IE** = infective endocarditis; **NaCl** = sodium chloride; **PYR** = pyrrolidonyl arylamidase;

©UWorld

Enterococcal endocarditis (representing up to 30% of nosocomial endocarditis cases) usually occurs in elderly men who have recently undergone manipulation of areas colonized by this organism. The genitourinary tract (eg, cystoscopy) is the most common portal of entry; gastrointestinal (eg, colonoscopy) or obstetric procedures are also risk factors. Enterococci can also cause urinary tract infections (most common), intraabdominal and pelvic infections, and wound infections. Enterococci are typically gamma-hemolytic (no hemolysis on agar), **catalase-negative**, pyrrolidonyl arylamidase-positive, Lancefield Group D **gram-positive cocci** that can grow in **hypertonic (6.5%) saline and bile**. The most common species of enterococci (formerly classified under the genus *Streptococcus*) are *Enterococcus faecalis* (80%-90%) and *Enterococcus faecium* (10%-15%).

Enterococci are resistant to many antibiotics and can be very difficult to treat. A cell wall-active agent (such as ampicillin) is often combined with an aminoglycoside for synergistic effect, but increasingly bacteria resistant to both aminoglycosides and β-lactams (including penicillinase-resistant types) are emerging. Strains with vancomycin or linezolid resistance have also appeared.

(Choice B) Dental extraction is associated with endocarditis caused by viridans group streptococci (VGS). In most cases, VGS cause subacute bacterial endocarditis in already abnormal heart valves (eg, congenital valvular abnormalities, valves damaged by rheumatic fever). VGS do not grow on hypertonic saline. In addition, almost all VGS species do not grow on bile (VGS are also considered bile-insoluble as they exhibit no cell lysis in the presence of bile, in contrast to the bile-soluble *S pneumoniae*).

(Choice C) Removal of a nasal polyp can cause transient bacteremia. Organisms that colonize the nose include *Corynebacterium* species, *Haemophilus* species, staphylococci, streptococci, and *Neisseria* species. Of these, staphylococci and streptococci may cause endocarditis, but the organism described displays characteristics of *Enterococcus*.

(Choice D) Sinus infections are usually caused by *S pneumoniae, Haemophilus influenzae*, or *Moraxella catarrhalis*. *S pneumoniae* would be a very rare cause of endocarditis and is usually identified by being bile-soluble and optochin-sensitive.

(Choice E) Skin biopsy is a benign procedure that would be unlikely to cause endocarditis. Skin is colonized with many bacteria, including *Staphylococcus* and *Streptococcus* species, *Corynebacterium* species, and *Bacillus* species.

Educational objective:
Enterococcus is a component of the normal colonic and urogenital flora and is capable of growing in hypertonic saline and bile. It is gamma-

(Choice B) Dental extraction is associated with endocarditis caused by viridans group streptococci (VGS). In most cases, VGS cause subacute bacterial endocarditis in already abnormal heart valves (eg, congenital valvular abnormalities, valves damaged by rheumatic fever). VGS do not grow on hypertonic saline. In addition, almost all VGS species do not grow on bile (VGS are also considered bile-insoluble as they exhibit no cell lysis in the presence of bile, in contrast to the bile-soluble *S pneumoniae*).

(Choice C) Removal of a nasal polyp can cause transient bacteremia. Organisms that colonize the nose include *Corynebacterium* species, *Haemophilus* species, staphylococci, streptococci, and *Neisseria* species. Of these, staphylococci and streptococci may cause endocarditis, but the organism described displays characteristics of *Enterococcus*.

(Choice D) Sinus infections are usually caused by *S pneumoniae*, *Haemophilus influenzae*, or *Moraxella catarrhalis*. *S pneumoniae* would be a very rare cause of endocarditis and is usually identified by being bile-soluble and optochin-sensitive.

(Choice E) Skin biopsy is a benign procedure that would be unlikely to cause endocarditis. Skin is colonized with many bacteria, including *Staphylococcus* and *Streptococcus* species, *Corynebacterium* species, and *Bacillus* species.

Educational objective:

Enterococcus is a component of the normal colonic and urogenital flora and is capable of growing in hypertonic saline and bile. It is gamma-hemolytic, catalase-negative, and pyrrolidonyl arylamidase-positive. Genitourinary instrumentation or catheterization has been associated with enterococcal endocarditis.

References

- Enterococcal endocarditis on native and prosthetic valves: A review of clinical and prognostic factors with emphasis on hospital-acquired infections as a major determinant of outcome.
- It's not easy being green: The viridans group streptococci, with a focus on pediatric clinical manifestations.

Microbiology	Cardiovascular System	Endocarditis
Subject	System	Topic

Copyright © UWorld. All rights reserved.

An 8-year-old boy with acute lymphoblastic leukemia receiving maintenance chemotherapy is hospitalized due to fever and neutropenia. Treatment with broad spectrum intravenous antibiotics is begun and the patient's fever resolves. His neutrophil count increases with granulocyte colony-stimulating factor therapy and blood cultures remain negative. On day 5 of hospitalization, the patient experiences nausea, abdominal cramping, and 6-8 episodes of watery diarrhea. Temperature is 37.7 C (100 F). Physical examination shows mild lower abdominal tenderness without guarding or rebound tenderness. Stool testing for occult blood is negative. Which of the following is the single best stool test to establish the cause of this patient's diarrhea?

- A. Culture on sorbitol-MacConkey agar
- B. Enzyme immunoassay for bacterial antigen
- C. Latex agglutination for viral antigens
- D. Microscopy after modified acid-fast staining
- E. Microscopy for ova and parasites
- F. PCR for bacterial gene encoding a toxin

Submit

An 8-year-old boy with acute lymphoblastic leukemia receiving maintenance chemotherapy is hospitalized due to fever and neutropenia. Treatment with broad spectrum intravenous antibiotics is begun and the patient's fever resolves. His neutrophil count increases with granulocyte colony-stimulating factor therapy and blood cultures remain negative. On day 5 of hospitalization, the patient experiences nausea, abdominal cramping, and 6-8 episodes of watery diarrhea. Temperature is 37.7 C (100 F). Physical examination shows mild lower abdominal tenderness without guarding or rebound tenderness. Stool testing for occult blood is negative. Which of the following is the single best stool test to establish the cause of this patient's diarrhea?

- A. Culture on sorbitol-MacConkey agar (5%)
- B. Enzyme immunoassay for bacterial antigen (17%)
- C. Latex agglutination for viral antigens (3%)
- D. Microscopy after modified acid-fast staining (3%)
- E. Microscopy for ova and parasites (5%)
- ✓ F. PCR for bacterial gene encoding a toxin (64%)

Omitted
Correct answer
F

64%
Answered correctly

01 sec
Time Spent

02/15/2020
Last Updated

Explanation

This child who developed diarrhea, nausea, and abdominal cramping while on antibiotics should be tested for ***Clostridium difficile* infection** (CDI). Patients who develop acute diarrhea (≥3 loose stool in 24 hours), particularly those with risk factors (eg, hospitalization, antibiotic use),

This child who developed diarrhea, nausea, and abdominal cramping while on antibiotics should be tested for ***Clostridium difficile* infection** (CDI). Patients who develop acute diarrhea (≥3 loose stool in 24 hours), particularly those with risk factors (eg, hospitalization, antibiotic use), should have stool samples sent for evaluation.

Diagnostic testing includes:

- **Nucleic acid amplication test** (NAAT): Uses a **polymerase chain reaction** to detect genes present in toxigenic strains (eg, **toxin B-encoding gene**). This test is **highly sensitive and specific** for toxigenic strains but does not distinguish active toxin production and may lead to overdiagnosis in asymptomatic carriers.
- **Enzyme immunoassays** (EIA): Uses antibodies to detect *C difficile* antigens or toxins. EIA for bacterial toxins is highly specific but has **poor sensitivity** as large amounts of toxin are required. In contrast, EIA for glutamate dehydrogenase (a bacterial antigen expressed by all *C difficile* isolates) has better sensitivity but cannot distinguish toxin-producing strains.

NAAT is considered the most sensitive method for diagnosis of CDI in patients with clinical symptoms. EIA for bacterial toxins can be added as part of a multistep algorithm to increase specificity of active disease; however, it is not recommended for use alone **(Choice B)**.

(Choice A) Culture on sorbitol-MacConkey agar is used to diagnose *Escherichia coli* O157:H7 (ie, enterohemorrhagic *E coli* [EHEC]). EHEC presents with bloody diarrhea; this patient's nonbloody diarrhea and recent antibiotic exposure makes CDI more likely.

(Choice C) Latex agglutination for viral antigens is used to diagnose rotavirus, which causes nonbloody diarrhea, vomiting, and fever; disease can be particularly severe in immunocompromised patients. However, incubation time is typically <48 hours, and it is unlikely that this patient would develop an infection after 5 days in the hospital.

(Choice D) Modified acid-fast staining is used to diagnose cryptosporidium infection, which causes chronic diarrhea (particularly in HIV-infected patients). This patient's current hospitalization and antibiotic use make CDI more likely.

(Choice E) Stool ova and parasites are used to diagnose intestinal parasites (eg, *Giardia*, *Entamoeba*). These can cause diarrhea, which can be particularly severe in immunocompromised patients, but are unlikely to occur after 5 days in the hospital. *Entamoeba histolytica* typically presents with bloody stool after travel to resource-limited countries.

- **Enzyme immunoassays** (EIA): Uses antibodies to detect *C difficile* antigens or toxins. EIA for bacterial toxins is highly specific but has **poor sensitivity** as large amounts of toxin are required. In contrast, EIA for glutamate dehydrogenase (a bacterial antigen expressed by all *C difficile* isolates) has better sensitivity but cannot distinguish toxin-producing strains.

NAAT is considered the most sensitive method for diagnosis of CDI in patients with clinical symptoms. EIA for bacterial toxins can be added as part of a multistep algorithm to increase specificity of active disease; however, it is not recommended for use alone **(Choice B)**.

(Choice A) Culture on sorbitol-MacConkey agar is used to diagnose *Escherichia coli* O157:H7 (ie, enterohemorrhagic *E coli* [EHEC]). EHEC presents with bloody diarrhea; this patient's nonbloody diarrhea and recent antibiotic exposure makes CDI more likely.

(Choice C) Latex agglutination for viral antigens is used to diagnose rotavirus, which causes nonbloody diarrhea, vomiting, and fever; disease can be particularly severe in immunocompromised patients. However, incubation time is typically <48 hours, and it is unlikely that this patient would develop an infection after 5 days in the hospital.

(Choice D) Modified acid-fast staining is used to diagnose cryptosporidium infection, which causes chronic diarrhea (particularly in HIV-infected patients). This patient's current hospitalization and antibiotic use make CDI more likely.

(Choice E) Stool ova and parasites are used to diagnose intestinal parasites (eg, *Giardia*, *Entamoeba*). These can cause diarrhea, which can be particularly severe in immunocompromised patients, but are unlikely to occur after 5 days in the hospital. *Entamoeba histolytica* typically presents with bloody stool after travel to resource-limited countries.

Educational objective:
Clostridium difficile commonly presents with diarrhea and abdominal pain; hospitalization and antibiotic use increase the risk of contracting the disease. A nucleic acid amplication test is considered the most sensitive method for diagnosis of *C difficile* infection in patients with clinical symptoms.

Microbiology	Gastrointestinal & Nutrition	Clostridium difficile infection
Subject	System	Topic

Copyright © UWorld. All rights reserved.

A 53-year-old man comes to the emergency department due to 2 weeks of intermittent low-grade fevers and fatigue. Temperature is 38.5 C (101.3 F), blood pressure is 120/80 mm Hg, pulse is 92/min, and respirations are 16/min. On cardiovascular examination, an early diastolic murmur is present and best heard at the left sternal edge. Subungual splinter hemorrhages are seen. Laboratory study results show leukocytosis and an elevated erythrocyte sedimentation rate. Blood cultures are drawn and grow gram-positive cocci that synthesize dextrans from sucrose. The organism contributing to this patient's current condition is also associated with which of the following?

- A. Anterior uveitis
- B. Colon cancer
- C. Dental caries
- D. Erythema nodosum
- E. Glomerulonephritis
- F. Migratory polyarthritis

Submit

A 53-year-old man comes to the emergency department due to 2 weeks of intermittent low-grade fevers and fatigue. Temperature is 38.5 C (101.3 F), blood pressure is 120/80 mm Hg, pulse is 92/min, and respirations are 16/min. On cardiovascular examination, an early diastolic murmur is present and best heard at the left sternal edge. Subungual splinter hemorrhages are seen. Laboratory study results show leukocytosis and an elevated erythrocyte sedimentation rate. Blood cultures are drawn and grow gram-positive cocci that synthesize dextrans from sucrose. The organism contributing to this patient's current condition is also associated with which of the following?

- A. Anterior uveitis (1%)
- B. Colon cancer (8%)
- ✓ C. Dental caries (72%)
- D. Erythema nodosum (4%)
- E. Glomerulonephritis (8%)
- F. Migratory polyarthritis (4%)

Omitted
Correct answer
C

72%
Answered correctly

02 secs
Time Spent

04/26/2020
Last Updated

Explanation

Viridans streptococci, notably *Streptococcus mutans* and *S sanguinis*, are normally present in the human mouth and are major contributors to tooth decay and the initiation of **dental caries**. These organisms also cause bacterial **endocarditis**, deep wound infections, abdominal abscesses, and septicemia. Viridans streptococci can **adhere** to tooth enamel and to fibrin-platelet aggregates on damaged heart valves due to

Viridans streptococci, notably *Streptococcus mutans* and *S sanguinis*, are normally present in the human mouth and are major contributors to tooth decay and the initiation of **dental caries**. These organisms also cause bacterial **endocarditis**, deep wound infections, abdominal abscesses, and septicemia. Viridans streptococci can **adhere** to tooth enamel and to fibrin-platelet aggregates on damaged heart valves due to their ability to produce insoluble extracellular polysaccharides (**dextrans**) using sucrose as a substrate. This colonization of host surfaces contributes to their ability to cause infection.

(Choice A) Anterior uveitis (inflammation of the iris) can be caused by infectious processes (eg, herpes viruses, syphilis, Lyme disease) and inflammatory conditions (eg, HLA-B27-related diseases, sarcoidosis). It is not associated with viridans streptococcal infections.

(Choice B) *S bovis* is associated with colon cancer, and patients with *S bovis* endocarditis should undergo colonoscopic evaluation to exclude neoplasia.

(Choice D) Erythema nodosum (erythematous to violaceous subcutaneous nodules usually appearing on the legs) is a nonspecific finding. It is associated with multiple bacterial infections, most commonly *S pyogenes* pharyngitis, but also *Staphylococcus aureus*, fungi (eg, coccidioidomycosis, histoplasmosis, blastomycosis), chlamydia, and others. It is also associated with Crohn disease, sarcoidosis, and other inflammatory conditions.

(Choices E and F) Poststreptococcal glomerulonephritis is a type III (immune complex-mediated) hypersensitivity reaction in which immune complexes deposit on the glomerular membrane and fix complement, leading to inflammation, renal dysfunction, hematuria, and nephritic range proteinuria. Migratory polyarthritis is a characteristic of rheumatic fever, an immune-mediated disease. These conditions typically follow infections with group A *Streptococcus* (*S pyogenes*), which does not produce dextrans.

Educational objective:
Viridans streptococci produce dextrans that aid them in colonizing host surfaces, such as dental enamel and heart valves. These organisms cause subacute bacterial endocarditis, classically in patients with preexisting cardiac valvular defects after dental manipulation.

Microbiology	Cardiovascular System	Endocarditis
Subject	System	Topic

tooth decay and the initiation of **dental caries**. These organisms also cause bacterial **endocarditis**, deep wound infections, abdominal abscesses, and septicemia. Viridans streptococci can **adhere** to tooth enamel and to fibrin-platelet aggregates on damaged heart valves due to their ability to produce insoluble extracellular polysaccharides (**dextrans**) using sucrose as a substrate. This colonization of host surfaces contributes to their ability to cause infection.

(Choice A) Anterior uveitis (inflammation of the iris) can be caused by infectious processes (eg, herpes viruses, syphilis, Lyme disease) and inflammatory conditions (eg, HLA-B27-related diseases, sarcoidosis). It is not associated with viridans streptococcal infections.

(Choice B) *S bovis* is associated with colon cancer, and patients with *S bovis* endocarditis should undergo colonoscopic evaluation to exclude neoplasia.

(Choice D) Erythema nodosum (erythematous to violaceous subcutaneous nodules usually appearing on the legs) is a nonspecific finding. It is associated with multiple bacterial infections, most commonly *S pyogenes* pharyngitis, but also *Staphylococcus aureus*, fungi (eg, coccidioidomycosis, histoplasmosis, blastomycosis), chlamydia, and others. It is also associated with Crohn disease, sarcoidosis, and other inflammatory conditions.

(Choices E and F) Poststreptococcal glomerulonephritis is a type III (immune complex-mediated) hypersensitivity reaction in which immune complexes deposit on the glomerular membrane and fix complement, leading to inflammation, renal dysfunction, hematuria, and nephritic range proteinuria. Migratory polyarthritis is a characteristic of rheumatic fever, an immune-mediated disease. These conditions typically follow infections with group A *Streptococcus* (*S pyogenes*), which does not produce dextrans.

Educational objective:
Viridans streptococci produce dextrans that aid them in colonizing host surfaces, such as dental enamel and heart valves. These organisms cause subacute bacterial endocarditis, classically in patients with preexisting cardiac valvular defects after dental manipulation.

Microbiology	Cardiovascular System	Endocarditis
Subject	System	Topic

Copyright © UWorld. All rights reserved.

A 22-year-old male presents to the emergency department complaining of fever, abdominal pain, and vomiting. He has had these symptoms for the past four days, but has not sought medical attention because of concerns over the cost of treatment. On examination, the patient appears acutely ill. There is right lower quadrant tenderness with rebound as well as a palpable mass. CT scan of the abdomen and pelvis demonstrates a periappendiceal fluid collection. Culture of this fluid would most likely isolate which of the following organisms?

A. *Staphylococcus aureus*

B. *Actinomyces*

C. *Candida albicans*

D. *Bacteroides fragilis*

E. *Entamoeba histolytica*

Submit

A 22-year-old male presents to the emergency department complaining of fever, abdominal pain, and vomiting. He has had these symptoms for the past four days, but has not sought medical attention because of concerns over the cost of treatment. On examination, the patient appears acutely ill. There is right lower quadrant tenderness with rebound as well as a palpable mass. CT scan of the abdomen and pelvis demonstrates a periappendiceal fluid collection. Culture of this fluid would most likely isolate which of the following organisms?

- A. *Staphylococcus aureus* (13%)
- B. *Actinomyces* (3%)
- C. *Candida albicans* (0%)
- ✓ D. *Bacteroides fragilis* (73%)
- E. *Entamoeba histolytica* (9%)

Omitted
Correct answer
D

73%
Answered correctly

02 secs
Time Spent

05/18/2020
Last Updated

Explanation

This patient is suffering from perforated appendicitis that has evolved into an intraabdominal abscess. Although most infections within the abdominal cavity are polymicrobial, *B. fragilis* is a common anaerobic gram-negative bacillus that is frequently isolated, and of the choices given, it is the most likely organism to be identified in the culture of this patient's abscess. This organism expresses unique surface polysaccharides that have been shown to favor abscess formation. In addition to *B. fragilis*, common bacterial isolates from intraabdominal infections include other members of the normal colonic flora such as *Escherichia coli*, enterococci, and streptococci.

Correct answer
D

Answered correctly

Time Spent

Last Updated

Explanation

This patient is suffering from perforated appendicitis that has evolved into an intraabdominal abscess. Although most infections within the abdominal cavity are polymicrobial, *B. fragilis* is a common anaerobic gram-negative bacillus that is frequently isolated, and of the choices given, it is the most likely organism to be identified in the culture of this patient's abscess. This organism expresses unique surface polysaccharides that have been shown to favor abscess formation. In addition to *B. fragilis*, common bacterial isolates from intraabdominal infections include other members of the normal colonic flora such as *Escherichia coli*, enterococci, and streptococci.

(Choice A) *S. aureus* is a gram-positive organism that can cause abscess formation on the skin, but is not typically isolated from an intraabdominal abscess.

(Choice B) *Actinomyces* species are anaerobic bacteria that can form abscesses in the cervicofacial region or abdominal cavity. However, they are much less common than *B. fragilis* and typically do not form abscesses this quickly.

(Choice C) *Candida albicans* can be isolated from an infection resulting from perforation of the proximal bowel such as a perforated peptic ulcer.

(Choice E) Infection with *E. histolytica* can result in the formation of an amebic liver abscess. This patient, however, has perforated appendicitis, which is not related to infection with *E. histolytica*.

Educational objective:
Intraabdominal infections are polymicrobial, with *B. fragilis* and *E. coli* being the most prominent organisms isolated.

Microbiology	Gastrointestinal & Nutrition	Appendicitis
Subject	System	Topic

Copyright © UWorld. All rights reserved.

A 65-year-old man comes to the office due to pain, redness, and swelling in his right calf. The patient is diagnosed with cellulitis and is started on clindamycin. A few days after starting treatment, he develops watery diarrhea and abdominal cramps. The patient is hospitalized, and complete blood count reveals leukocytosis. The toxin responsible for his current condition most directly impairs which of the following components of intestinal mucosal cells?

- A. Apical ion transport
- B. Cell membrane integrity
- C. Cytoskeleton integrity
- D. Mitochondrial energy production
- E. Ribosomal protein synthesis

Submit

A 65-year-old man comes to the office due to pain, redness, and swelling in his right calf. The patient is diagnosed with cellulitis and is started on clindamycin. A few days after starting treatment, he develops watery diarrhea and abdominal cramps. The patient is hospitalized, and complete blood count reveals leukocytosis. The toxin responsible for his current condition most directly impairs which of the following components of intestinal mucosal cells?

- A. Apical ion transport (23%)
- B. Cell membrane integrity (14%)
- ✓ C. Cytoskeleton integrity (53%)
- D. Mitochondrial energy production (0%)
- E. Ribosomal protein synthesis (7%)

Omitted
Correct answer
C

53%
Answered correctly

01 sec
Time Spent

06/08/2020
Last Updated

Explanation

***Clostridioides difficile* colitis**	
Risk factors	• Recent antibiotic use (eg, clindamycin) • Hospitalization • PPI

***Clostridioides difficile* colitis**	
Risk factors	• Recent antibiotic use (eg, clindamycin) • Hospitalization • PPI
Pathogenesis	• Disruption of intestinal flora → *C. difficile* overgrowth • Toxins A and B disrupt cytoskeleton integrity & stimulate inflammation
Clinical presentation	• Watery diarrhea (most common) • Fulminant pseudomembranous colitis/toxic megacolon
Diagnosis	• Stool PCR for genes specific to toxigenic strains
Treatment	• Oral vancomycin OR fidaxomicin • Metronidazole

PCR = polymerase chain reaction; **PPI** = proton pump inhibitor.

Clostridioides (formerly *Clostridium*) *difficile* is part of the gut's normal microbial flora in 2%-3% of healthy adults and in approximately 70% of healthy infants. Administration of **antibiotics** (eg, **clindamycin**, fluoroquinolones, and broad-spectrum penicillin) that are lethal to other commensal gut organisms can result in ***C. difficile* colitis** due to unchecked replication of pathogenic strains of *C. difficile*.

These strains produce **toxin A** and **toxin B**, which act synergistically, although toxin B is significantly more virulent. The toxins bind specific receptors on intestinal mucosal cells and are internalized, allowing them to inactivate Rho-regulatory proteins involved in actin cytoskeletal structure maintenance. The result is **loss of cytoskeleton integrity**, leading to cell rounding/retraction, disruption of intercellular tight junctions, and increased paracellular intestinal fluid secretion (eg, watery diarrhea). Both toxins also have **inflammatory effects** (eg, neutrophil recruitment) and can induce apoptosis, resulting in pain and **pseudomembrane** formation.

Clostridioides (formerly *Clostridium*) *difficile* is part of the gut's normal microbial flora in 2%-3% of healthy adults and in approximately 70% of healthy infants. Administration of **antibiotics** (eg, **clindamycin**, fluoroquinolones, and broad-spectrum penicillin) that are lethal to other commensal gut organisms can result in ***C. difficile* colitis** due to unchecked replication of pathogenic strains of *C. difficile*.

These strains produce **toxin A** and **toxin B**, which act synergistically, although toxin B is significantly more virulent. The toxins bind specific receptors on intestinal mucosal cells and are internalized, allowing them to inactivate Rho-regulatory proteins involved in actin cytoskeletal structure maintenance. The result is **loss of cytoskeleton integrity**, leading to cell rounding/retraction, disruption of intercellular tight junctions, and increased paracellular intestinal fluid secretion (eg, watery diarrhea). Both toxins also have **inflammatory effects** (eg, neutrophil recruitment) and can induce apoptosis, resulting in pain and **pseudomembrane** formation.

(Choice A) Apical ion transport is most directly affected by the cholera toxin (main exotoxin of *Vibrio cholerae*) through activation of adenylate cyclase, which leads to decreased salt reabsorption and increased transport of sodium and chloride out of the gut mucosal cell. Apical ion transporters can be indirectly affected by *C. difficile* toxins due to loss of cell polarity (secondary to cytoskeletal dysfunction).

(Choice B) Loss of cell membrane integrity is characteristic of alpha toxin lecithinase, one of many exotoxins released by *Clostridium perfringens*. *C. perfringens* can cause transient watery diarrhea. However, it is most frequently associated with clostridial myonecrosis (ie, gas gangrene), a rapidly progressive form of fasciitis associated with penetrating injury by soil-contaminated objects.

(Choice D) Mitochondria are the primary source of ATP in human cells. Cyanide and nucleoside reverse transcriptase inhibitors are examples of drugs associated with mitochondrial toxicity.

(Choice E) Ribosomal protein synthesis is inhibited by shiga and shiga-like toxins. Shiga toxin is the main exotoxin released by *Shigella* species; shiga-like toxin (ie, verotoxin) is produced by enterohemorrhagic *Escherichia coli* (eg, O157:H7). These toxins cause inflammatory diarrhea (eg, fever, pain, blood) 3-4 days after ingestion of contaminated food or water.

Educational objective:
Pathogenic *Clostridioides difficile* can proliferate due to loss of commensal gut flora following use of broad-spectrum antibiotics (eg, clindamycin). *C. difficile* toxins A and B exert their effects by stimulating an inflammatory reaction and disrupting the actin cytoskeletal structure. The result is pseudomembranous colitis characterized by crampy abdominal pain, watery diarrhea, and leukocytosis.

References

and increased paracellular intestinal fluid secretion (eg, watery diarrhea). Both toxins also have **inflammatory effects** (eg, neutrophil recruitment) and can induce apoptosis, resulting in pain and **pseudomembrane** formation.

(Choice A) Apical ion transport is most directly affected by the cholera toxin (main exotoxin of *Vibrio cholerae*) through activation of adenylate cyclase, which leads to decreased salt reabsorption and increased transport of sodium and chloride out of the gut mucosal cell. Apical ion transporters can be indirectly affected by *C. difficile* toxins due to loss of cell polarity (secondary to cytoskeletal dysfunction).

(Choice B) Loss of cell membrane integrity is characteristic of alpha toxin lecithinase, one of many exotoxins released by *Clostridium perfringens*. *C. perfringens* can cause transient watery diarrhea. However, it is most frequently associated with clostridial myonecrosis (ie, gas gangrene), a rapidly progressive form of fasciitis associated with penetrating injury by soil-contaminated objects.

(Choice D) Mitochondria are the primary source of ATP in human cells. Cyanide and nucleoside reverse transcriptase inhibitors are examples of drugs associated with mitochondrial toxicity.

(Choice E) Ribosomal protein synthesis is inhibited by shiga and shiga-like toxins. Shiga toxin is the main exotoxin released by *Shigella* species; shiga-like toxin (ie, verotoxin) is produced by enterohemorrhagic *Escherichia coli* (eg, O157:H7). These toxins cause inflammatory diarrhea (eg, fever, pain, blood) 3-4 days after ingestion of contaminated food or water.

Educational objective:

Pathogenic *Clostridioides difficile* can proliferate due to loss of commensal gut flora following use of broad-spectrum antibiotics (eg, clindamycin). *C. difficile* toxins A and B exert their effects by stimulating an inflammatory reaction and disrupting the actin cytoskeletal structure. The result is pseudomembranous colitis characterized by crampy abdominal pain, watery diarrhea, and leukocytosis.

References

- The role of toxin A and toxin B in Clostridium difficile infection.

Microbiology	Gastrointestinal & Nutrition	Clostridium difficile infection
Subject	System	Topic

Copyright © UWorld. All rights reserved.

A 52-year-old man is hospitalized due to 2 weeks of low-grade fever, malaise, anorexia, and fatigue. The patient has a history of bicuspid aortic valve and underwent aortic valve replacement a year ago. Physical examination reveals a new regurgitation murmur. Blood cultures repeatedly grow gram-positive cocci in clusters, which are identified as *Staphylococcus epidermidis*. This pathogen most likely demonstrates which of the following characteristics?

- A. Alpha hemolysis
- B. Mannitol fermentation
- C. Negative catalase test
- D. Negative coagulase test
- E. Novobiocin resistance
- F. Yellow pigment production

Submit

A 52-year-old man is hospitalized due to 2 weeks of low-grade fever, malaise, anorexia, and fatigue. The patient has a history of bicuspid aortic valve and underwent aortic valve replacement a year ago. Physical examination reveals a new regurgitation murmur. Blood cultures repeatedly grow gram-positive cocci in clusters, which are identified as *Staphylococcus epidermidis*. This pathogen most likely demonstrates which of the following characteristics?

- A. Alpha hemolysis (3%)
- B. Mannitol fermentation (2%)
- C. Negative catalase test (6%)
- ✓ D. Negative coagulase test (78%)
- E. Novobiocin resistance (8%)
- F. Yellow pigment production (1%)

Omitted
Correct answer
D

78%
Answered correctly

01 sec
Time Spent

04/12/2020
Last Updated

Explanation

Staphylococcus epidermidis is a low-virulence skin commensal that rarely causes infection in healthy patients. However, those with prosthetic devices (eg, indwelling catheters, **artificial heart valves**, artificial joints) are at risk because the pathogen produces adhesion and biofilm proteins that allow it to grow on artificial surfaces. *S epidermidis* is one of the most common contaminants of blood cultures, but infection should be suspected when multiple blood cultures grow the bacteria and/or the patient has symptoms of clinical infection such as fever, malaise, and

Explanation

Staphylococcus epidermidis is a low-virulence skin commensal that rarely causes infection in healthy patients. However, those with prosthetic devices (eg, indwelling catheters, **artificial heart valves**, artificial joints) are at risk because the pathogen produces adhesion and biofilm proteins that allow it to grow on artificial surfaces. *S epidermidis* is one of the most common contaminants of blood cultures, but infection should be suspected when multiple blood cultures grow the bacteria and/or the patient has symptoms of clinical infection such as fever, malaise, and leukocytosis.

Staphylococcus species are gram-positive cocci that grow in grape-like clusters. They are differentiated from streptococci by the catalase test: Streptococci are catalase-negative whereas staphylococci are **catalase-positive (Choice C)**. Further speciation of staphylococci leverages the coagulase test (the ability to clot blood plasma), which differentiates *S aureus* from **coagulase-negative staphylococci** such as *S epidermidis*, *S haemolyticus*, and *S saprophyticus*.

(Choice A) Alpha hemolysis (partial, green hemolysis when plated on blood agar) is a feature of viridans streptococci, a common cause of infective endocarditis. Staphylococci species are either beta-hemolytic (complete hemolysis) or gamma-hemolytic (no hemolysis). *S epidermidis* is gamma-hemolytic.

(Choice B) *S aureus* and *S haemolyticus* can ferment mannitol, but *S epidermidis* cannot.

(Choice E) Novobiocin is an antibiotic that can be applied to plated colonies to differentiate *S saprophyticus* from other coagulase-negative *Staphylococcus* species: *S saprophyticus* is novobiocin-resistant whereas others, such as *S epidermidis*, are novobiocin-sensitive.

(Choice F) *S aureus* produces a golden-yellow surface pigment, which accounts for its name (*aureus* means gold in Latin). *S aureus* is a common cause of infective endocarditis and osteomyelitis, particularly in intravenous drug users.

Educational objective:
Staphylococcus epidermidis, a gram-positive coccus that grows in clusters, is a skin commensal that is a common cause of infection in patients with prosthetic devices such as artificial joints or heart valves. Unlike *S aureus*, *S epidermidis* is coagulase-negative. Unlike *S saprophyticus* (another coagulase-negative staphylococci species), *S epidermidis* is susceptible to novobiocin.

Settings

1 2 3 4 5 6 7 8 9 10 11 12 13 14 15 16 17 18 19 20 21 22 23 24 25 26 27 28 29 30

Item 16 of 38
Question Id: 679

Mark | Previous | Next | Full Screen | Tutorial | Lab Values | Notes | Calculator | Reverse Color | Text Zoom | Settings

Staphylococcus epidermidis is a low virulence skin commensal that rarely causes infection in healthy patients. However, those with prosthetic

Exhibit Display

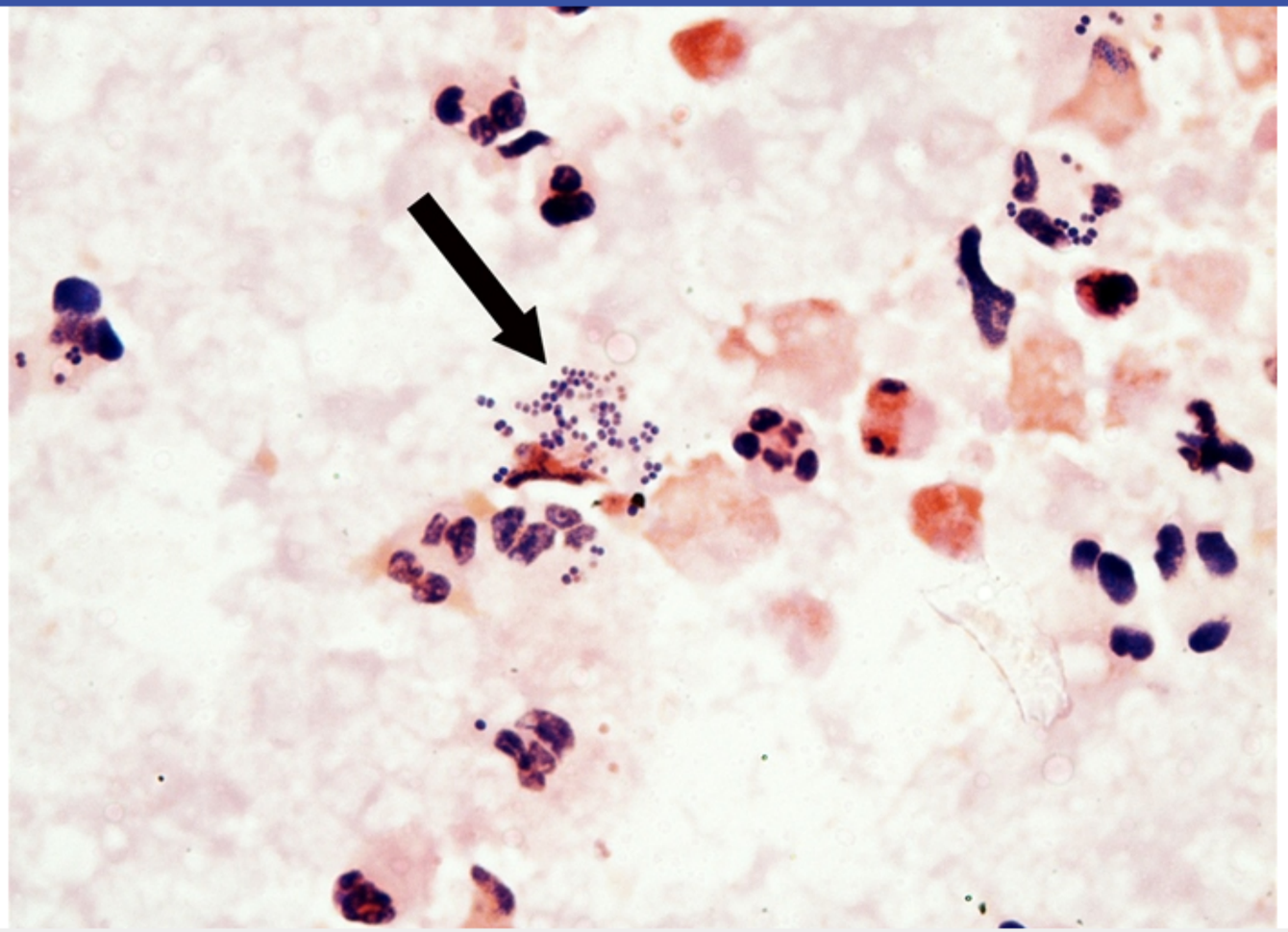

Zoom In | Zoom Out | Reset | Add To New Card | Existing Card

Subject System Topic

Block Time Remaining: 00:00:33
TUTOR

3 | Feedback | Suspend | End Block

that allow it to grow on artificial surfaces. *S epidermidis* is one of the most common contaminants of blood cultures, but infection should be suspected when multiple blood cultures grow the bacteria and/or the patient has symptoms of clinical infection such as fever, malaise, and leukocytosis.

Staphylococcus species are gram-positive cocci that grow in grape-like clusters. They are differentiated from streptococci by the catalase test: Streptococci are catalase-negative whereas staphylococci are **catalase-positive (Choice C)**. Further speciation of staphylococci leverages the coagulase test (the ability to clot blood plasma), which differentiates *S aureus* from **coagulase-negative staphylococci** such as *S epidermidis*, *S haemolyticus*, and *S saprophyticus*.

(Choice A) Alpha hemolysis (partial, green hemolysis when plated on blood agar) is a feature of viridans streptococci, a common cause of infective endocarditis. Staphylococci species are either beta-hemolytic (complete hemolysis) or gamma-hemolytic (no hemolysis). *S epidermidis* is gamma-hemolytic.

(Choice B) *S aureus* and *S haemolyticus* can ferment mannitol, but *S epidermidis* cannot.

(Choice E) Novobiocin is an antibiotic that can be applied to plated colonies to differentiate *S saprophyticus* from other coagulase-negative *Staphylococcus* species: *S saprophyticus* is novobiocin-resistant whereas others, such as *S epidermidis*, are novobiocin-sensitive.

(Choice F) *S aureus* produces a golden-yellow surface pigment, which accounts for its name (*aureus* means gold in Latin). *S aureus* is a common cause of infective endocarditis and osteomyelitis, particularly in intravenous drug users.

Educational objective:
Staphylococcus epidermidis, a gram-positive coccus that grows in clusters, is a skin commensal that is a common cause of infection in patients with prosthetic devices such as artificial joints or heart valves. Unlike *S aureus*, *S epidermidis* is coagulase-negative. Unlike *S saprophyticus* (another coagulase-negative staphylococci species), *S epidermidis* is susceptible to novobiocin.

Microbiology	Cardiovascular System	Endocarditis
Subject	System	Topic

Copyright © UWorld. All rights reserved.

A 5-month-old boy is brought to the emergency department due to poor feeding, weakness, and complete loss of extremity muscle tone. Vaccinations are up to date, and there is no significant medical history. The patient receives formula as his sole source of nutrition except for occasional fruit juice and honey. Which of the following is most likely to confirm the diagnosis in this patient?

A. Blood test for liver enzymes

B. Blood test for viral titers

C. Stool test for bacterial toxins

D. Stool test for occult blood

E. Urine test for amino acids

F. Urine test for glucose and ketones

Submit

A 5-month-old boy is brought to the emergency department due to poor feeding, weakness, and complete loss of extremity muscle tone. Vaccinations are up to date, and there is no significant medical history. The patient receives formula as his sole source of nutrition except for occasional fruit juice and honey. Which of the following is most likely to confirm the diagnosis in this patient?

- A. Blood test for liver enzymes (5%)
- B. Blood test for viral titers (0%)
- ✓ C. Stool test for bacterial toxins (80%)
- D. Stool test for occult blood (0%)
- E. Urine test for amino acids (4%)
- F. Urine test for glucose and ketones (7%)

Omitted
Correct answer
C

80%
Answered correctly

01 sec
Time Spent

06/08/2020
Last Updated

Explanation

Infant botulism	
Pathogenesis	• Ingestion of *Clostridium botulinum* spores (eg, environmental dust/soil, honey) • Spores colonize gastrointestinal tract & produce botulinum toxin • Botulinum toxin inhibits presynaptic acetylcholine release

Infant botulism	
Pathogenesis	• Ingestion of *Clostridium botulinum* spores (eg, environmental dust/soil, honey) • Spores colonize gastrointestinal tract & produce botulinum toxin • Botulinum toxin inhibits presynaptic acetylcholine release
Clinical presentation	• Age <12 months • Constipation, poor feeding, hypotonia • Oculobulbar palsies (eg, absent gag reflex, ptosis) • Symmetric, descending flaccid paralysis
Diagnosis	• Classic presentation • Confirmation by identification of stool *C botulinum* spores or toxins

This 5-month-old patient has consumed **honey**, a food notorious for contamination with ***Clostridium botulinum*** spores. When an infant consumes *C botulinum* spores, the bacteria can germinate in the gastrointestinal tract. Bacteriolysis releases **botulinum toxin**, which is absorbed systemically and blocks release of acetylcholine from cholinergic presynaptic terminals.

Constipation is usually the first manifestation of **infant botulism**, followed days to weeks later by **mild weakness**, lethargy, and **reduced feeding**. In rare, severe cases, infants can have weakened suckling and crying, diminished gag reflex, and symmetric, descending flaccid paralysis with loss of head control that can cause the infant to appear "floppy." In contrast, adult botulism usually results from ingestion of preformed toxin (eg, contaminated canned foods) and is almost always very severe.

While infant botulism can be diagnosed based on the clinical presentation and food consumption history, the diagnosis is usually confirmed through identification of *C botulinum* spores or **toxin in stool** samples.

(Choice A) Measurement of blood liver enzyme levels can indicate damage to hepatic cells in hereditary fructose intolerance (genetic deficiency in aldolase B). Although patients with fructose intolerance can have poor feeding shortly after juice and honey are added to the diet, other classic manifestations include hypoglycemia, vomiting, and hepatomegaly rather than loss of extremity muscle tone.

Diagnosis	• Confirmation by identification of stool *C botulinum* spores or toxins

This 5-month-old patient has consumed **honey**, a food notorious for contamination with ***Clostridium botulinum*** spores. When an infant consumes *C botulinum* spores, the bacteria can germinate in the gastrointestinal tract. Bacteriolysis releases **botulinum toxin**, which is absorbed systemically and blocks release of acetylcholine from cholinergic presynaptic terminals.

Constipation is usually the first manifestation of **infant botulism**, followed days to weeks later by **mild weakness**, lethargy, and **reduced feeding**. In rare, severe cases, infants can have weakened suckling and crying, diminished gag reflex, and symmetric, descending flaccid paralysis with loss of head control that can cause the infant to appear "floppy." In contrast, adult botulism usually results from ingestion of preformed toxin (eg, contaminated canned foods) and is almost always very severe.

While infant botulism can be diagnosed based on the clinical presentation and food consumption history, the diagnosis is usually confirmed through identification of *C botulinum* spores or **toxin in stool** samples.

(Choice A) Measurement of blood liver enzyme levels can indicate damage to hepatic cells in hereditary fructose intolerance (genetic deficiency in aldolase B). Although patients with fructose intolerance can have poor feeding shortly after juice and honey are added to the diet, other classic manifestations include hypoglycemia, vomiting, and hepatomegaly rather than loss of extremity muscle tone.

(Choice B) Serum viral titers are frequently used in the evaluation of patients with viral hepatitis or suspected Epstein-Barr or cytomegalovirus infections. Poor feeding with loss of extremity muscle tone is more characteristic of infant botulism.

(Choice D) Allergic proctocolitis in infants can present after introduction of different food groups, and the diagnosis can be supported by stool studies that are positive for gross or occult blood. However, these infants usually appear well despite persistent diarrhea and/or rectal bleeding.

(Choice E) Patients with amino acids in their urine may have an inborn error of metabolism (eg, maple syrup urine disease) with symptoms usually manifesting in the neonatal period or early infancy.

(Choice F) High levels of urine glucose and ketones, together with hyperglycemia and metabolic acidosis, can support a diagnosis of diabetic ketoacidosis.

Educational objective:
Infant botulism can result from consumption of honey, which frequently contains *C botulinum* spores that can germinate and produce botulinum

preformed toxin (eg, contaminated canned foods) and is almost always very severe.

While infant botulism can be diagnosed based on the clinical presentation and food consumption history, the diagnosis is usually confirmed through identification of *C botulinum* spores or **toxin in stool** samples.

(Choice A) Measurement of blood liver enzyme levels can indicate damage to hepatic cells in hereditary fructose intolerance (genetic deficiency in aldolase B). Although patients with fructose intolerance can have poor feeding shortly after juice and honey are added to the diet, other classic manifestations include hypoglycemia, vomiting, and hepatomegaly rather than loss of extremity muscle tone.

(Choice B) Serum viral titers are frequently used in the evaluation of patients with viral hepatitis or suspected Epstein-Barr or cytomegalovirus infections. Poor feeding with loss of extremity muscle tone is more characteristic of infant botulism.

(Choice D) Allergic proctocolitis in infants can present after introduction of different food groups, and the diagnosis can be supported by stool studies that are positive for gross or occult blood. However, these infants usually appear well despite persistent diarrhea and/or rectal bleeding.

(Choice E) Patients with amino acids in their urine may have an inborn error of metabolism (eg, maple syrup urine disease) with symptoms usually manifesting in the neonatal period or early infancy.

(Choice F) High levels of urine glucose and ketones, together with hyperglycemia and metabolic acidosis, can support a diagnosis of diabetic ketoacidosis.

Educational objective:
Infant botulism can result from consumption of honey, which frequently contains *C botulinum* spores that can germinate and produce botulinum toxin. Symptoms of infant botulism include constipation, mild weakness, lethargy, poor feeding, and, in severe cases, flaccid paralysis. The diagnosis can be confirmed by identification of *C botulinum* spores or toxins in the stool.

Microbiology	Gastrointestinal & Nutrition	Botulism
Subject	System	Topic

Copyright © UWorld. All rights reserved.

A 68-year-old woman with end-stage renal disease receiving intermittent hemodialysis comes to the office due to back pain. She says that she may have "pulled a muscle" while getting out of her car a week ago; since then she has had progressively worsening back pain. She has no leg numbness or weakness but reports malaise and fatigue. The patient also has hypertension and type 2 diabetes mellitus and was treated several weeks ago for staphylococcal bacteremia associated with the dialysis catheter. Her temperature is 38 C (100.4 F). On examination, she has tenderness over the upper lumbar vertebrae without overlying skin changes. The straight leg raise test is negative. Which of the following is the best next step in management of this patient?

A. Analgesics and close follow-up

B. CT myelogram

C. Lumbar puncture

D. MRI of the spine

E. Serum protein electrophoresis

Submit

A 68-year-old woman with end-stage renal disease receiving intermittent hemodialysis comes to the office due to back pain. She says that she may have "pulled a muscle" while getting out of her car a week ago; since then she has had progressively worsening back pain. She has no leg numbness or weakness but reports malaise and fatigue. The patient also has hypertension and type 2 diabetes mellitus and was treated several weeks ago for staphylococcal bacteremia associated with the dialysis catheter. Her temperature is 38 C (100.4 F). On examination, she has tenderness over the upper lumbar vertebrae without overlying skin changes. The straight leg raise test is negative. Which of the following is the best next step in management of this patient?

- A. Analgesics and close follow-up (7%)
- B. CT myelogram (10%)
- C. Lumbar puncture (13%)
- ✓ D. MRI of the spine (51%)
- E. Serum protein electrophoresis (15%)

Omitted
Correct answer
D

51%
Answered correctly

02 secs
Time Spent

01/27/2020
Last Updated

Explanation

Although this patient believes her back pain may be due to a muscle sprain, her presentation (localized bony back pain, low-grade fever, recent staphylococcal bacteremia) suggests **vertebral osteomyelitis**. Bacteria can access the spine by hematogenous spread from a distant infection (eg, skin or soft tissue, intravenous catheter), direct invasion from trauma or local spinal procedures (eg, lumbar puncture, spinal surgery), or direct spread from adjacent soft tissue infection. **Hematogenous** spread is most common as the adult vertebral bone has a very rich and vascular

Although this patient believes her back pain may be due to a muscle sprain, her presentation (localized bony back pain, low-grade fever, recent staphylococcal bacteremia) suggests **vertebral osteomyelitis**. Bacteria can access the spine by hematogenous spread from a distant infection (eg, skin or soft tissue, intravenous catheter), direct invasion from trauma or local spinal procedures (eg, lumbar puncture, spinal surgery), or direct spread from adjacent soft tissue infection. **Hematogenous** spread is most common as the adult vertebral bone has a very rich and vascular marrow. Increasing age can cause the nutrient arteries to develop a "corkscrew" anatomy, which allows bacteria to more easily penetrate the marrow cavity and cause local infection.

Bacteremia due to intravascular devices (eg, hemodialysis catheters) increases risk of health care-related vertebral osteomyelitis. Offending organisms include ***Staphylococcus*** (most common is *S aureus* or coagulase-negative staphylococci) and various gram-negative organisms (eg, *Pseudomonas*). Vertebral osteomyelitis should be suspected in patients with new or worsening back pain, fever, and recent endocarditis or bacteremia (especially *S aureus*). It should also be suspected if there are new neurologic findings and fever, with or without back pain. Initial evaluation includes **blood cultures** and **MRI** of the spine, which is the most sensitive imaging method for diagnosing vertebral osteomyelitis.

(Choice A) Analgesics and close follow-up are recommended for musculoskeletal causes of low back pain, but this patient's clinical findings (fever, localized bony tenderness, recent bacteremia) are concerning for more serious etiologies and require further evaluation.

(Choice B) CT myelogram, which can diagnose spinal stenosis or other vertebral pathology (including osteomyelitis), is performed by injecting contrast into the lumbar spine prior to CT imaging. However, it is more invasive than MRI and usually reserved for patients who cannot undergo MRI (eg, those with pacemaker, metallic implants).

(Choice C) Lumbar puncture is typically used for diagnosing meningitis and has a low yield for diagnosing vertebral osteomyelitis. CT-guided bone biopsy is usually preferred for isolating the organism after imaging confirms the diagnosis of vertebral osteomyelitis.

(Choice E) Serum protein electrophoresis is typically done to evaluate for monoclonal gammopathies (eg, multiple myeloma). Although multiple myeloma can present with back pain, this patient's fever and recent bacteremia make vertebral osteomyelitis more likely.

Educational objective:
Vertebral osteomyelitis should be suspected in patients with new or worsening back pain, fever, and recent endocarditis or bacteremia (especially *Staphylococcus aureus*). It should also be suspected if there are new neurologic findings and fever with or without back pain. MRI of the spine is preferred for diagnosis.

evaluation includes **blood cultures** and **MRI** of the spine, which is the most sensitive imaging method for diagnosing vertebral osteomyelitis.

(Choice A) Analgesics and close follow-up are recommended for musculoskeletal causes of low back pain, but this patient's clinical findings (fever, localized bony tenderness, recent bacteremia) are concerning for more serious etiologies and require further evaluation.

(Choice B) CT myelogram, which can diagnose spinal stenosis or other vertebral pathology (including osteomyelitis), is performed by injecting contrast into the lumbar spine prior to CT imaging. However, it is more invasive than MRI and usually reserved for patients who cannot undergo MRI (eg, those with pacemaker, metallic implants).

(Choice C) Lumbar puncture is typically used for diagnosing meningitis and has a low yield for diagnosing vertebral osteomyelitis. CT-guided bone biopsy is usually preferred for isolating the organism after imaging confirms the diagnosis of vertebral osteomyelitis.

(Choice E) Serum protein electrophoresis is typically done to evaluate for monoclonal gammopathies (eg, multiple myeloma). Although multiple myeloma can present with back pain, this patient's fever and recent bacteremia make vertebral osteomyelitis more likely.

Educational objective:
Vertebral osteomyelitis should be suspected in patients with new or worsening back pain, fever, and recent endocarditis or bacteremia (especially *Staphylococcus aureus*). It should also be suspected if there are new neurologic findings and fever with or without back pain. MRI of the spine is preferred for diagnosis.

References

- 2015 Infectious Diseases Society of America (IDSA) Clinical Practice Guidelines for the Diagnosis and Treatment of Native Vertebral Osteomyelitis in Adults.
- Health care associated hematogenous pyogenic vertebral osteomyelitis: a severe and potentially preventable infectious disease

Microbiology	Rheumatology/Orthopedics & Sports	Osteomyelitis
Subject	System	Topic

Copyright © UWorld. All rights reserved.

A 24-year-old woman comes to the office due to 2 days of burning during urination and increased urinary frequency and urgency. The patient has had no fever, chills, nausea, vomiting, flank pain, or vaginal discharge, but reports darkening of the urine. She has no other medical conditions and does not use tobacco, alcohol, or drugs. The patient is sexually active with her boyfriend and takes an oral contraceptive for birth control. Vital signs are within normal limits. Physical examination shows mild suprapubic tenderness. There is no costovertebral angle tenderness. Which of the following pathogens is most likely responsible for this patient's symptoms?

- A. *Candida albicans*
- B. *Chlamydia trachomatis*
- C. *Escherichia coli*
- D. *Gardnerella vaginalis*
- E. Group B streptococcus
- F. *Klebsiella pneumoniae*
- G. *Neisseria gonorrhoeae*
- H. *Proteus mirabilis*
- I. *Pseudomonas aeruginosa*
- J. *Staphylococcus aureus*

Submit

1 2 3 4 5 6 7 8 9 10 11 12 13 14 15 16 17 18 19 20 21 22 23 24 25 26 27 28 29 30

A 24-year-old woman comes to the office due to 2 days of burning during urination and increased urinary frequency and urgency. The patient has had no fever, chills, nausea, vomiting, flank pain, or vaginal discharge, but reports darkening of the urine. She has no other medical conditions and does not use tobacco, alcohol, or drugs. The patient is sexually active with her boyfriend and takes an oral contraceptive for birth control. Vital signs are within normal limits. Physical examination shows mild suprapubic tenderness. There is no costovertebral angle tenderness. Which of the following pathogens is most likely responsible for this patient's symptoms?

- A. *Candida albicans* (1%)
- B. *Chlamydia trachomatis* (3%)
- ✓ C. *Escherichia coli* (86%)
- D. *Gardnerella vaginalis* (0%)
- E. Group B streptococcus (1%)
- F. *Klebsiella pneumoniae* (0%)
- G. *Neisseria gonorrhoeae* (1%)
- H. *Proteus mirabilis* (3%)
- I. *Pseudomonas aeruginosa* (0%)
- J. *Staphylococcus aureus* (0%)

Omitted
Correct answer
C

86%
Answered correctly

01 sec
Time Spent

02/09/2020
Last Updated

Explanation

This patient with painful urination, urinary frequency/urgency, and suprapubic tenderness has **acute cystitis**, a urinary tract infection (UTI) confined to the bladder. Most cases arise when **fecal organisms** gain access to the urethral meatus and subsequently ascend into the bladder. ***Escherichia coli***, a gram-negative coliform bacteria, causes >70% of UTIs; other Enterobacteriaceae organisms, such as *Klebsiella pneumoniae* and *Proteus mirabilis* **(Choices F and H)**, are also common but much less so than *E coli*. **Women** develop UTIs much more often than men due to the proximity of the anus and vaginal introitus and the short length of the female urethra.

(Choice A) *Candida albicans* is a common cause of vulvovaginitis, which usually presents with vaginal discharge, burning, and pruritis.

(Choices B and G) *Chlamydia trachomatis* and *Neisseria gonorrhoeae* are leading sexually transmitted pathogens. Although urethritis symptoms (eg, dysuria) can occur, most symptomatic women have significant mucopurulent vaginal discharge. Suprapubic tenderness is less common.

(Choice D) Bacterial vaginosis occurs when normal vaginal flora (eg, *Lactobacillus*) is replaced with facultative anaerobes such as *Gardnerella vaginalis*. Most cases are asymptomatic, but some individuals have thin, whitish vaginal discharge and a fishy vaginal odor.

(Choice E) Group B streptococcus commonly colonizes the genital and gastrointestinal tract and rarely causes infection. However, it can be passed to infants during vaginal birth, leading to early neonatal sepsis.

(Choices I and J) *Pseudomonas aeruginosa* and *Staphylococcus aureus* are uncommon UTI pathogens in healthy, young women. However, they can cause cystitis in those who have recently received antibiotics or have been hospitalized. Both organisms are much less common than *E coli*.

Educational objective:
Urinary tract infections are most common in women and are typically caused by enteric pathogens. *Escherichia coli* is the leading pathogen.

Microbiology	Renal, Urinary Systems & Electrolytes	Urinary tract infection
Subject	System	Topic

Copyright © UWorld. All rights reserved.

A 37-year-old man is brought to the emergency department following a motor vehicle accident in which he was the unrestrained driver. Paramedics report that his breath smelled of alcohol at the scene. En route to the hospital, the patient receives 2 L intravenous normal saline. In the emergency department, his blood pressure is 100/60 mm Hg, pulse is 130/min, and respirations are 44/min. He is admitted directly to the intensive care unit, where he is intubated and placed on mechanical ventilation. A decision is made to insert a central venous catheter. In addition to sterile draping during the procedure, which of the following actions would be most likely to prevent intravascular catheter-related infections?

A. Alcohol-based hand scrub prior to beginning the procedure

B. Daily application of topical mupirocin at the catheter site

C. Insertion of the catheter in the femoral vein

D. One dose of intravenous vancomycin prior to catheter insertion

E. Replacement of the catheter every 7 days

Submit

A 37-year-old man is brought to the emergency department following a motor vehicle accident in which he was the unrestrained driver. Paramedics report that his breath smelled of alcohol at the scene. En route to the hospital, the patient receives 2 L intravenous normal saline. In the emergency department, his blood pressure is 100/60 mm Hg, pulse is 130/min, and respirations are 44/min. He is admitted directly to the intensive care unit, where he is intubated and placed on mechanical ventilation. A decision is made to insert a central venous catheter. In addition to sterile draping during the procedure, which of the following actions would be most likely to prevent intravascular catheter-related infections?

- ✓ A. Alcohol-based hand scrub prior to beginning the procedure (46%)
- B. Daily application of topical mupirocin at the catheter site (9%)
- C. Insertion of the catheter in the femoral vein (1%)
- D. One dose of intravenous vancomycin prior to catheter insertion (12%)
- E. Replacement of the catheter every 7 days (29%)

Omitted
Correct answer
A

46%
Answered correctly

01 sec
Time Spent

01/26/2020
Last Updated

Explanation

Central venous catheters (CVCs) are commonly used for hemodynamic monitoring and administration of fluids and medications in critically ill patients. **Infection** originating from the patient's skin flora or bacteria on the hands of health care workers is one of the major complications of CVCs. **Gram-positive cocci**, primarily coagulase-negative staphylococci and *Staphylococcus aureus*, account for the majority of these infections.

The Centers for Disease Control and Prevention recommend the following steps to reduce CVC infections:

Explanation

Central venous catheters (CVCs) are commonly used for hemodynamic monitoring and administration of fluids and medications in critically ill patients. **Infection** originating from the patient's skin flora or bacteria on the hands of health care workers is one of the major complications of CVCs. **Gram-positive cocci**, primarily coagulase-negative staphylococci and *Staphylococcus aureus*, account for the majority of these infections.

The Centers for Disease Control and Prevention recommend the following steps to reduce CVC infections:

- **Hand hygiene** with an alcohol sanitizer or soap and water prior to donning sterile gloves
- Maximal **barrier precautions** during insertion (surgical mask, sterile gloves, long-sleeved surgical gown, and a large sterile sheet drape)
- Preparation of the insertion site with chlorhexidine antiseptic
- Use of subclavian or internal jugular insertion sites (femoral vein has a higher risk of infection) **(Choice C)**
- Prompt removal of the catheter when it is no longer needed

(Choice B) Topical antimicrobial ointments do not reduce the rate of CVC-related infections and are associated with increased risk of antimicrobial resistance and *Candida* colonization.

(Choice D) Oral or parenteral antibiotics have not been found to reduce the incidence of CVC-related infections. In addition, the prophylactic use of vancomycin has been found to increase the risk of vancomycin-resistant enterococcus.

(Choice E) Catheter replacement at scheduled intervals does not reduce infection rates. Routine replacement of CVCs is not necessary for functional catheters with no evidence of infection.

Educational objective:
The most important steps for prevention of central venous catheter infections are as follows:

- Proper hand hygiene
- Full barrier precautions during insertion
- Chlorhexidine skin disinfection
- Avoidance of the femoral insertion site
- Removal of the catheter when it is no longer needed

- Maximal **barrier precautions** during insertion (surgical mask, sterile gloves, long-sleeved surgical gown, and a large sterile sheet drape)
- Preparation of the insertion site with chlorhexidine antiseptic
- Use of subclavian or internal jugular insertion sites (femoral vein has a higher risk of infection) **(Choice C)**
- Prompt removal of the catheter when it is no longer needed

(Choice B) Topical antimicrobial ointments do not reduce the rate of CVC-related infections and are associated with increased risk of antimicrobial resistance and *Candida* colonization.

(Choice D) Oral or parenteral antibiotics have not been found to reduce the incidence of CVC-related infections. In addition, the prophylactic use of vancomycin has been found to increase the risk of vancomycin-resistant enterococcus.

(Choice E) Catheter replacement at scheduled intervals does not reduce infection rates. Routine replacement of CVCs is not necessary for functional catheters with no evidence of infection.

Educational objective:
The most important steps for prevention of central venous catheter infections are as follows:

- Proper hand hygiene
- Full barrier precautions during insertion
- Chlorhexidine skin disinfection
- Avoidance of the femoral insertion site
- Removal of the catheter when it is no longer needed

References

- Beyond the bundle--journey of a tertiary care medical intensive care unit to zero central line-associated bloodstream infections.

Microbiology	Cardiovascular System	Catheter related bloodstream infection
Subject	System	Topic

Copyright © UWorld. All rights reserved.

A 27-year-old man comes to the emergency department due to several hours of right foot pain and swelling. Last night, he was working in the barn and stepped on an old nail. This morning, the patient awoke with right foot pain near the injury site that has increased throughout the day and is accompanied by progressive swelling. He has no significant past medical history and takes no medications. Temperature is 38.1 C (100.6 F), blood pressure is 135/75 mm Hg, and pulse is 95/min. The right foot is swollen with some erythema around the injury site. Radiographic imaging reveals gas in the tissues. On urgent surgical exploration, extensive tissue necrosis is present. Culture from the site reveals gram-positive rods. Which of the following best describes the mechanism of action of the toxin responsible for the necrotic effects seen in this patient?

- A. Actin depolymerization
- B. Carbohydrate degradation
- C. Elongation factor ribosylation
- D. Phospholipid splitting
- E. Plasminogen activation
- F. Presynaptic acetylcholine release
- G. T cell hyperstimulation

Submit

A 27-year-old man comes to the emergency department due to several hours of right foot pain and swelling. Last night, he was working in the barn and stepped on an old nail. This morning, the patient awoke with right foot pain near the injury site that has increased throughout the day and is accompanied by progressive swelling. He has no significant past medical history and takes no medications. Temperature is 38.1 C (100.6 F), blood pressure is 135/75 mm Hg, and pulse is 95/min. The right foot is swollen with some erythema around the injury site. Radiographic imaging reveals gas in the tissues. On urgent surgical exploration, extensive tissue necrosis is present. Culture from the site reveals gram-positive rods. Which of the following best describes the mechanism of action of the toxin responsible for the necrotic effects seen in this patient?

- A. Actin depolymerization (8%)
- B. Carbohydrate degradation (7%)
- C. Elongation factor ribosylation (10%)
- ✓ D. Phospholipid splitting (61%)
- E. Plasminogen activation (1%)
- F. Presynaptic acetylcholine release (7%)
- G. T cell hyperstimulation (2%)

Omitted
Correct answer
D

61%
Answered correctly

01 sec
Time Spent

06/03/2020
Last Updated

Explanation

Mechanism of action of bacterial toxins		
Organism	**Toxin**	**Microbiology**
C. diphtheriae	Diphtheria toxin	Inactivates EF-2 via ribosylation, thus inhibiting host cell protein synthesis
P. aeruginosa	Exotoxin A	Inactivates EF-2 via ribosylation, thus inhibiting host cell protein synthesis
S. Aureus	Enterotoxin	Superantigen that acts locally in the GI tract causing vomiting
	TSS toxin	Superantigen that stimulates T-cells leading to widespread cytokine release and shock
C. difficile	Cytotoxin B	Induces actin depolymerization leading to mucosal cell death, necrosis of colonic mucosal surfaces, & pseudomembrane formation
C. botulinum	Botulinum toxin	Blocks the presynaptic release of acetycholine at the neuromuscular junction resulting in flaccid paralysis
		Disinhibits adenylate cyclase via G_i ADP

1 2 3 4 5 6 7 8 9 10 11 12 13 14 15 16 17 18 19 20 21 22 23 24 25 26 27 28 29 30

		widespread cytokine release and shock
C. difficile	Cytotoxin B	Induces actin depolymerization leading to mucosal cell death, necrosis of colonic mucosal surfaces, & pseudomembrane formation
C. botulinum	Botulinum toxin	Blocks the presynaptic release of acetycholine at the neuromuscular junction resulting in flaccid paralysis
B. pertussis	Pertussis toxin	Disinhibits adenylate cyclase via G_i ADP ribosylation, increasing cAMP production in the host cell; causes increased histamine sensitivity & phagocyte dysfunction
V. cholerae	Cholera toxin	Activates adenylate cyclase via G_s ADP ribosylation, increasing cAMP production in host cell; causes secretory diarrhea, dehydration, & electrolyte imbalances

©UWorld

This patient likely has **gas gangrene** due to *Clostridium perfringens* (toxin-producing gram-positive rods). **Lecithinase** is the main **toxin** of *C perfringens*; its concentration correlates with its lethal and **necrotic** effects. Lecithinase, also known as phospholipase C or alpha toxin, catalyzes the splitting of **phospholipid** molecules. It hydrolyzes lecithin-containing lipoprotein complexes in cell membranes, causing cell lysis (including erythrocyte hemolysis), tissue necrosis, and edema. (In contrast, human phospholipase A2 catalyzes arachidonic acid release from phospholipid cell membranes in the first step of leukotriene, thromboxane, and prostaglandin synthesis.) *C perfringens* has at least 12 toxins, of which phospholipase C is the most injurious.

©UWorld

This patient likely has **gas gangrene** due to *Clostridium perfringens* (toxin-producing gram-positive rods). **Lecithinase** is the main **toxin** of *C perfringens*; its concentration correlates with its lethal and **necrotic** effects. Lecithinase, also known as phospholipase C or alpha toxin, catalyzes the splitting of **phospholipid** molecules. It hydrolyzes lecithin-containing lipoprotein complexes in cell membranes, causing cell lysis (including erythrocyte hemolysis), tissue necrosis, and edema. (In contrast, human phospholipase A2 catalyzes arachidonic acid release from phospholipid cell membranes in the first step of leukotriene, thromboxane, and prostaglandin synthesis.) *C perfringens* has at least 12 toxins, of which phospholipase C is the most injurious.

C perfringens uses **carbohydrates** for energy. Its rapid metabolism of muscle tissue carbohydrates produces significant amounts of **gas**, which can be demonstrated radiographically by plain film x-ray or CT scan **(Choice B)**.

(Choices A and F) Actin depolymerization and inhibition of presynaptic acetylcholine release are the mechanisms of action of *C difficile* cytotoxin B and *C botulinum* botulinum toxin, respectively.

(Choice C) Inactivation of elongation factor-2 through ribosylation describes the mechanism of action for diphtheria toxin.

(Choice E) Plasminogen activators such as streptokinase, urokinase, and tissue plasminogen activator convert plasminogen to plasmin. Of these 3 enzymes, only streptokinase - an exotoxin released by *Streptococcus pyogenes* (group A *Streptococcus*) - is a bacterial product.

(Choice G) Certain *Staphylococcus aureus*-produced toxins act as superantigens by hyperstimulating T cells and causing massive cytokine production. Examples include enterotoxin (causes food poisoning) and toxic shock syndrome toxin.

Educational objective:
Lecithinase, also known as alpha toxin, is the main toxin produced by *Clostridium perfringens*. Its function is to degrade lecithin, a component of cellular phospholipid membranes, leading to membrane destruction, cell death, and widespread necrosis and hemolysis.

Microbiology	Rheumatology/Orthopedics & Sports	Clostridial myonecrosis
Subject	System	Topic

Copyright © UWorld. All rights reserved.

A 24-year-old man comes to the emergency department due to severe nausea and vomiting 2 hours after a church picnic. He ate chicken salad that had been sitting out in the sun. The patient has no prior medical conditions. Temperature is 37.2 C (98.9 F), blood pressure is 126/84 mm Hg, and pulse is 86/min. No abdominal tenderness is present, and bowel sounds are normal. Blood cell counts and serum chemistry studies are within normal limits. Symptoms improve significantly within several hours with supportive care. Which of the following is the most likely cause of this patient's symptoms?

A. Bacterial exotoxin production in the gut

B. Bacterial invasion of the gut mucosa

C. Ingestion of preformed enterotoxin

D. Microbial attachment to the intestinal surface

E. Systemic absorption of luminal endotoxin

Submit

A 24-year-old man comes to the emergency department due to severe nausea and vomiting 2 hours after a church picnic. He ate chicken salad that had been sitting out in the sun. The patient has no prior medical conditions. Temperature is 37.2 C (98.9 F), blood pressure is 126/84 mm Hg, and pulse is 86/min. No abdominal tenderness is present, and bowel sounds are normal. Blood cell counts and serum chemistry studies are within normal limits. Symptoms improve significantly within several hours with supportive care. Which of the following is the most likely cause of this patient's symptoms?

A. Bacterial exotoxin production in the gut (9%)

B. Bacterial invasion of the gut mucosa (2%)

✓ C. Ingestion of preformed enterotoxin (85%)

D. Microbial attachment to the intestinal surface (1%)

E. Systemic absorption of luminal endotoxin (1%)

Omitted
Correct answer
C

85%
Answered correctly

01 sec
Time Spent

03/27/2020
Last Updated

Explanation

Major pathologic mechanisms of foodborne illness		
Enterotoxin ingested	*Staphylococcus aureus* *Bacillus cereus*	• **Quick onset** (1-6 hours) • **Vomiting** predominant

Major pathologic mechanisms of foodborne illness		
Enterotoxin ingested	*Staphylococcus aureus* *Bacillus cereus*	• **Quick onset** (1-6 hours) • **Vomiting** predominant
Enterotoxin made in intestine	*Clostridium perfringens* ETEC/STEC *Vibrio cholerae*	• **Delayed** onset (>1 day) • Watery/bloody **diarrhea**
Bacterial epithelial invasion	*Campylobacter jejuni* Nontyphoidal salmonella *Listeria monocytogenes*	• Variable onset • Watery/bloody **diarrhea** • **Fever** • Systemic illness (*Listeria*)

ETEC = enterotoxigenic *Escherichia coli*; STEC = Shiga toxin-producing *E coli*.

Enterotoxigenic *Staphylococcus aureus* is a leading cause of foodborne illness. This pathogen inoculates food during unsanitary preparation by an asymptomatic carrier. Storage of the food at room temperature for extended periods (eg, picnic, pot luck meal) allows the bacteria to proliferate and generate a heat-stable **enterotoxin**. Ingestion of the **preformed** toxin leads to **rapid-onset illness** that includes nausea, **vomiting**, and abdominal pain. Occasionally, mild fever and diarrhea may also be present. Symptoms resolve in a few hours with symptomatic care.

Because the disease is due to the ingestion of a preformed toxin, no person-to-person transmission occurs. However, outbreaks may arise when people eat the same contaminated food at an event or party. High risk foods include dairy products, produce, precooked meat, eggs, and mayonnaise-based **salads** (eg, chicken salad).

A similar clinical picture of rapid-onset nausea, vomiting, and abdominal cramping can be seen with food-borne illness due to *Bacillus cereus*, which also produces a heat-stable enterotoxin. *B cereus* characteristically contaminates starchy foods (eg, rice); illness is often associated with reheated rice.

(Choices A, B, and D) Foodborne illness can also be caused by other bacterial mechanisms, such as:

Enterotoxigenic *Staphylococcus aureus* is a leading cause of foodborne illness. This pathogen inoculates food during unsanitary preparation by an asymptomatic carrier. Storage of the food at room temperature for extended periods (eg, picnic, pot luck meal) allows the bacteria to proliferate and generate a heat-stable **enterotoxin**. Ingestion of the **preformed** toxin leads to **rapid-onset illness** that includes nausea, **vomiting**, and abdominal pain. Occasionally, mild fever and diarrhea may also be present. Symptoms resolve in a few hours with symptomatic care.

Because the disease is due to the ingestion of a preformed toxin, no person-to-person transmission occurs. However, outbreaks may arise when people eat the same contaminated food at an event or party. High risk foods include dairy products, produce, precooked meat, eggs, and mayonnaise-based **salads** (eg, chicken salad).

A similar clinical picture of rapid-onset nausea, vomiting, and abdominal cramping can be seen with food-borne illness due to *Bacillus cereus*, which also produces a heat-stable enterotoxin. *B cereus* characteristically contaminates starchy foods (eg, rice); illness is often associated with reheated rice.

(Choices A, B, and D) Foodborne illness can also be caused by other bacterial mechanisms, such as:

- Enterotoxin production within the intestine by enterotoxigenic *Escherichia coli* (ETEC) and *Vibrio cholera*, whose toxins cause watery diarrhea, and enterohemorrhagic *E coli* (EHEC) and *Shigella*, whose toxins cause inflammatory/bloody diarrhea
- Bacterial invasion of the intestinal mucosa by *Salmonella*, enteroinvasive *E coli* (EIEC), and *Campylobacter jejuni* causes inflammatory/bloody diarrhea
- Enteropathogenic *E coli* (EPEC) attaches to enterocytes and effaces their surface, resulting in watery diarrhea; this strain does not produce toxins

However, gastroenteritis due to these bacteria generally takes **>24 hours** to manifest, as the bacteria require time to proliferate and subsequently produce enterotoxin and/or invade the intestinal epithelium.

(Choice E) Most gram-negative enteric pathogens contain endotoxin (lipopolysaccharide) that is released upon cell lysis. However, endotoxin released in the gastrointestinal tract is not typically absorbed in sufficient quantities to cause systemic illness. Endotoxin-mediated illness (eg, sepsis) occurs when gram-negative bacteria are present in the bloodstream.

Educational objective:

A similar clinical picture of rapid-onset nausea, vomiting, and abdominal cramping can be seen with food-borne illness due to *Bacillus cereus*, which also produces a heat-stable enterotoxin. *B cereus* characteristically contaminates starchy foods (eg, rice); illness is often associated with reheated rice.

(Choices A, B, and D) Foodborne illness can also be caused by other bacterial mechanisms, such as:

- Enterotoxin production within the intestine by enterotoxigenic *Escherichia coli* (ETEC) and *Vibrio cholera*, whose toxins cause watery diarrhea, and enterohemorrhagic *E coli* (EHEC) and *Shigella*, whose toxins cause inflammatory/bloody diarrhea
- Bacterial invasion of the intestinal mucosa by *Salmonella*, enteroinvasive *E coli* (EIEC), and *Campylobacter jejuni* causes inflammatory/bloody diarrhea
- Enteropathogenic *E coli* (EPEC) attaches to enterocytes and effaces their surface, resulting in watery diarrhea; this strain does not produce toxins

However, gastroenteritis due to these bacteria generally takes **>24 hours** to manifest, as the bacteria require time to proliferate and subsequently produce enterotoxin and/or invade the intestinal epithelium.

(Choice E) Most gram-negative enteric pathogens contain endotoxin (lipopolysaccharide) that is released upon cell lysis. However, endotoxin released in the gastrointestinal tract is not typically absorbed in sufficient quantities to cause systemic illness. Endotoxin-mediated illness (eg, sepsis) occurs when gram-negative bacteria are present in the bloodstream.

Educational objective:
Staphylococcal food poisoning is mediated by the ingestion of a preformed, heat-stable enterotoxin that induces rapid-onset (<6 hours) nausea and vomiting. Most cases arise due to improper food handling and storage. Common culprit foods include eggs, dairy products, and mayonnaise-based salads.

Microbiology	Gastrointestinal & Nutrition	Foodborne illness
Subject	System	Topic

Copyright © UWorld. All rights reserved.

Volunteer studies are used to determine the infectious dose of *Salmonella* required to cause gastroenteritis. The curve obtained during the studies is shown in the diagram as line 2. Which of the following organisms could be represented by line 1 on this diagram?

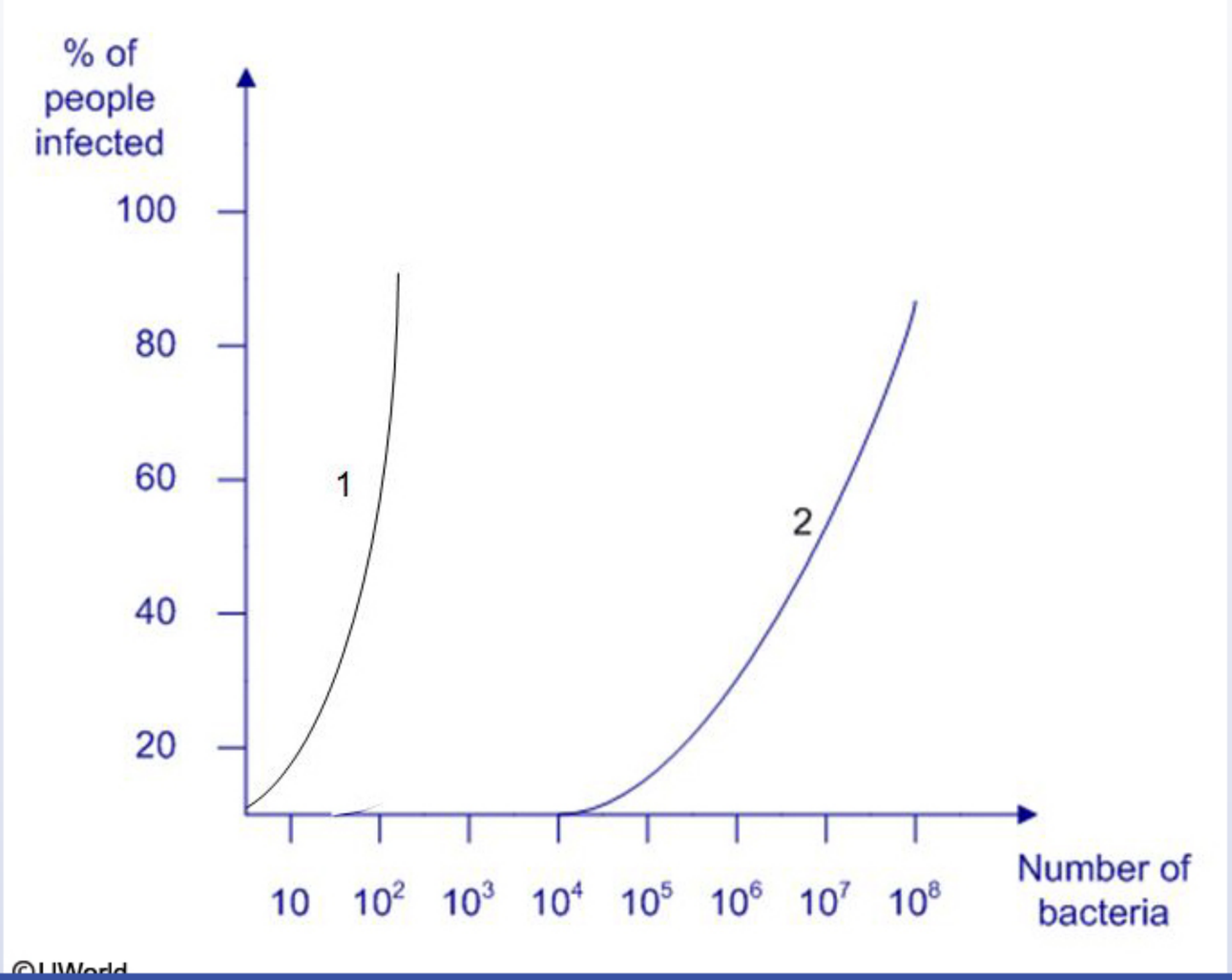

©UWorld

1 2 3 4 5 6 7 8 9 10 11 12 13 14 15 16 17 18 19 20 21 22 23 24 25 26 27 28 29 30

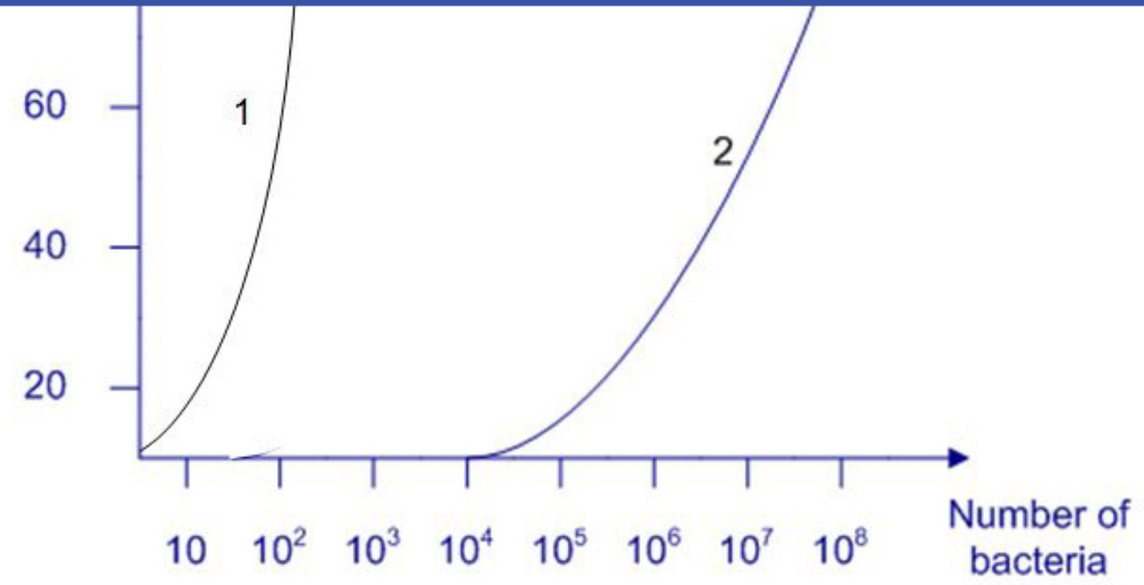

©UWorld

A. *Clostridium perfringens*

B. Enterotoxigenic *Escherichia coli*

C. *Shigella flexneri*

D. *Vibrio cholerae*

E. *Vibrio parahaemolyticus*

Submit

1 2 3 4 5 6 7 8 9 10 11 12 13 14 15 16 17 18 19 20 21 22 23 24 25 26 27 28 29 30

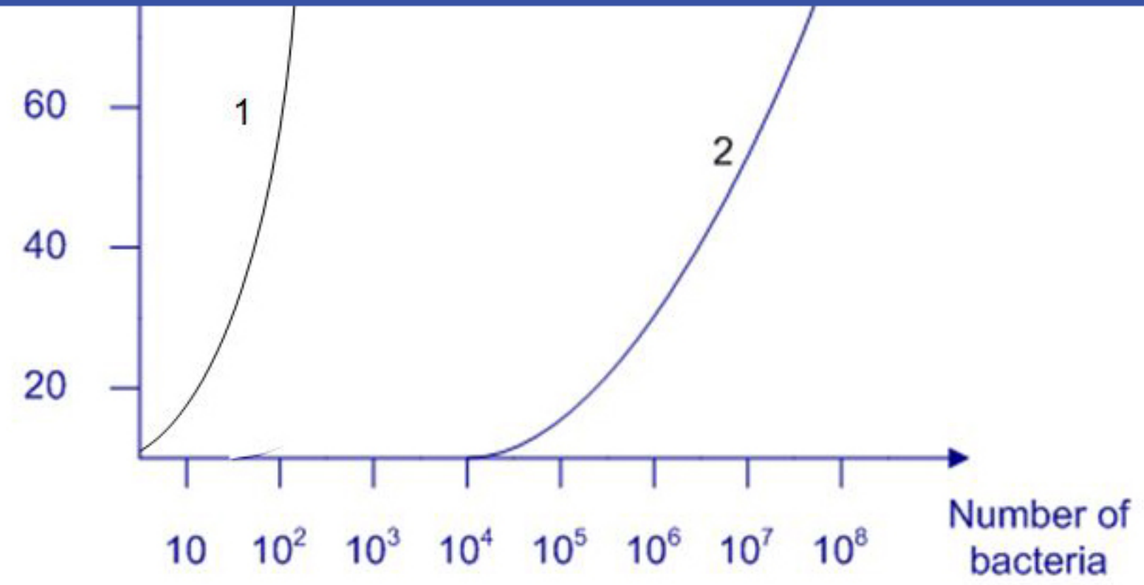

©UWorld

A. *Clostridium perfringens* (4%)

B. Enterotoxigenic *Escherichia coli* (9%)

✓ C. *Shigella flexneri* (73%)

D. *Vibrio cholerae* (12%)

E. *Vibrio parahaemolyticus* (0%)

Omitted
Correct answer

73%
Answered correctly

04 secs
Time Spent

03/29/2020
Last Updated

1 2 3 4 5 6 7 8 9 10 11 12 13 14 15 16 17 18 19 20 21 22 23 24 25 26 27 28 29 30

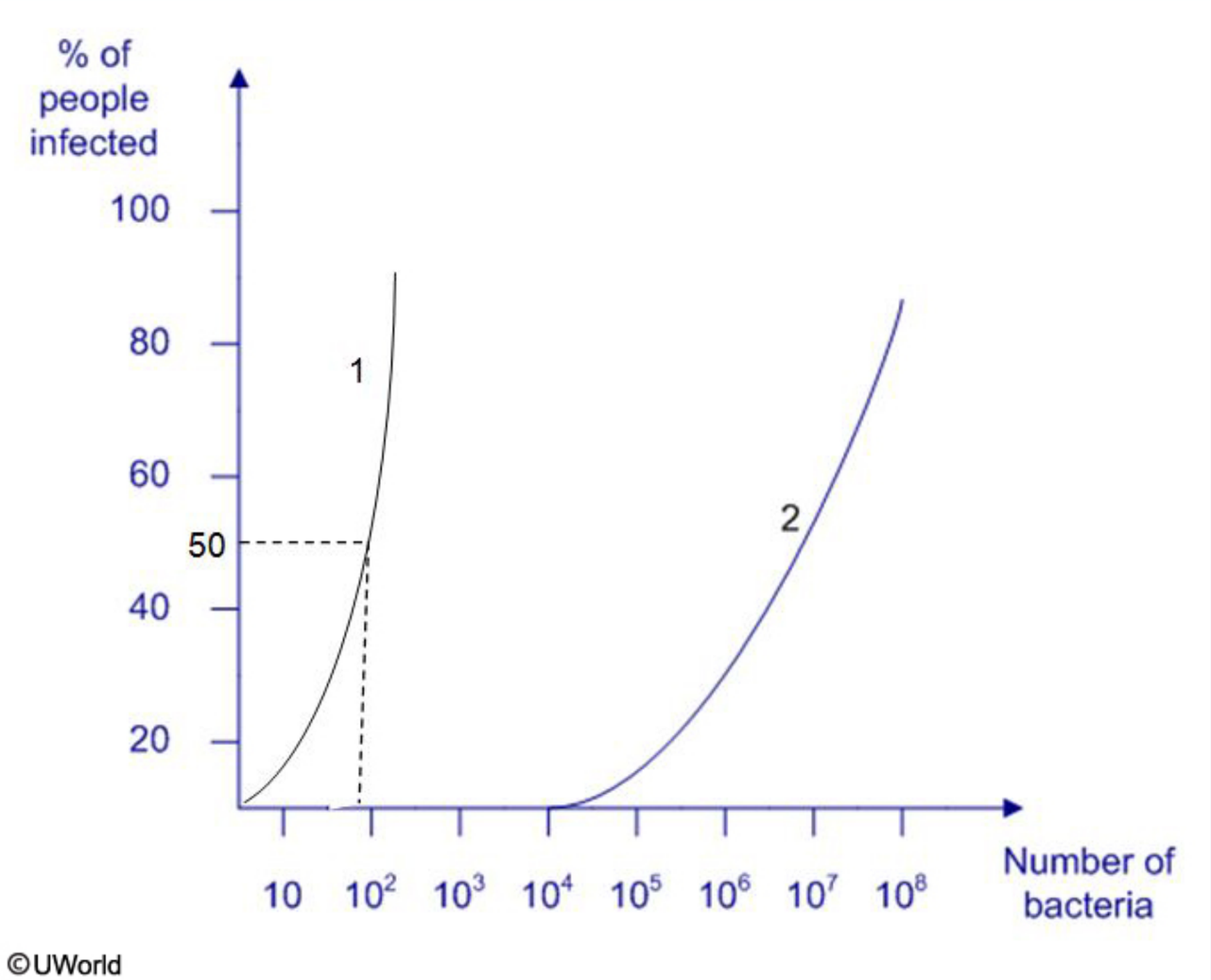

The **50% infectious** dose (ID_{50}) corresponds to the minimum number of organisms required to cause disease in 50% of affected individuals. The organism in Line 1 has an ID_{50} ~10^2. Depending on the age and condition of the host and on the species of ***Shigella***, as few as 10 *Shigella*

1 2 3 4 5 6 7 8 9 10 11 12 13 14 15 16 17 18 19 20 21 22 23 24 25 26 27 28 29 30

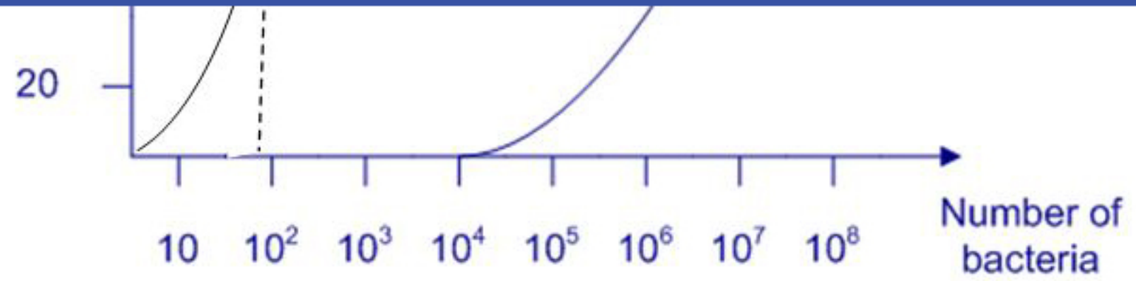

©UWorld

The **50% infectious** dose (ID_{50}) corresponds to the minimum number of organisms required to cause disease in 50% of affected individuals. The organism in Line 1 has an ID_{50} ~10^2. Depending on the age and condition of the host and on the species of ***Shigella***, as few as 10 *Shigella* organisms can cause disease. For example, the ID_{50} for *S dysenteriae* is 10, for *S flexneri* is 100, and for *S sonnei* is 500. *Shigella* is able to invade tissues and is highly adapted to surviving the acidity of the stomach and the bacteriostatic action of bile. The incubation period for shigellosis is 24-72 hours. Disease begins with watery diarrhea and progresses to fever, abdominal pain, dysentery, and tenesmus (painful rectal spasm associated with the urge to defecate but little passage of stool). A much larger inoculum of *Salmonella* (approximately 10^7) is required for successful infection in a susceptible host.

Other organisms that can cause diarrhea with only a small inoculum include *Campylobacter jejuni* (around 500 cells), *Entamoeba histolytica* (as few as 1-10 organisms), and *Giardia lamblia* (as few as 1-10 organisms).

(Choices A, B, D, and E) In general, the ID_{50} for *Salmonella*, *Vibrio*, *Clostridium perfringens*, and *Escherichia coli* are high (10^4-10^8).

Educational objective:
Depending on the age and condition of the host and the species of *Shigella*, as few as 10-500 cells can cause infection.

Microbiology	Gastrointestinal & Nutrition	Acute diarrhea
Subject	System	Topic

Copyright © UWorld. All rights reserved.

A 57-year-old woman is hospitalized with high-grade fevers, chills, and right upper abdominal pain. The patient lives in Wisconsin and has no history of international travel. Her temperature is 40 C (104 F). Physical examination of the abdomen shows rebound tenderness. Laboratory studies show elevated aspartate and alanine aminotransferases. Imaging studies reveal a fluid-filled cavity within the right lobe of the liver as shown below.

Which of the following microorganism/route combinations is most likely to be the cause of this patient's infection?

A. *Chlamydia trachomatis* due to ascending cholangitis

B. Cytomegalovirus by direct invasion from a nearby source

C. *Entamoeba histolytica* due to a penetrating stab wound

D. *Staphylococcus aureus* by hematogenous route

E. *Streptococcus pneumoniae* by portal vein

Submit

A 57-year-old woman is hospitalized with high-grade fevers, chills, and right upper abdominal pain. The patient lives in Wisconsin and has no history of international travel. Her temperature is 40 C (104 F). Physical examination of the abdomen shows rebound tenderness. Laboratory studies show elevated aspartate and alanine aminotransferases. Imaging studies reveal a fluid-filled cavity within the right lobe of the liver as shown below.

1 2 3 4 5 6 7 8 9 10 11 12 13 14 15 16 17 18 19 20 21 22 23 24 25 26 27 28 29 30

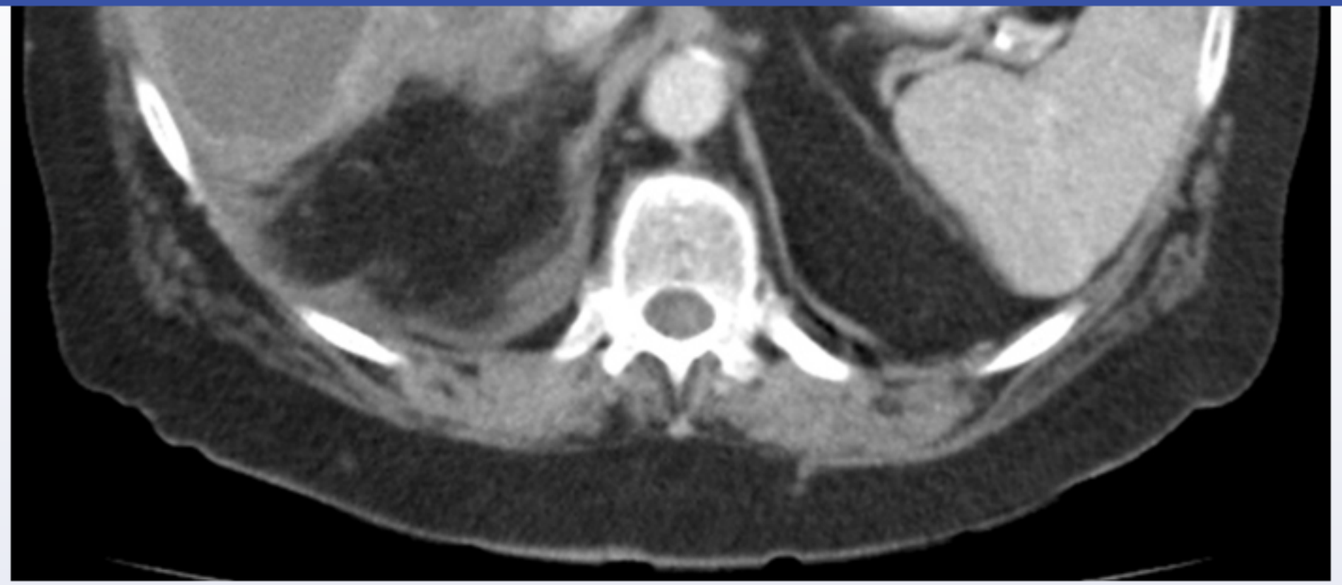

Which of the following microorganism/route combinations is most likely to be the cause of this patient's infection?

A. *Chlamydia trachomatis* due to ascending cholangitis

B. Cytomegalovirus by direct invasion from a nearby source

C. *Entamoeba histolytica* due to a penetrating stab wound

D. *Staphylococcus aureus* by hematogenous route

E. *Streptococcus pneumoniae* by portal vein

Submit

1 2 3 4 5 6 7 8 9 10 11 12 13 14 15 16 17 18 19 20 21 22 23 24 25 26 27 28 29 30

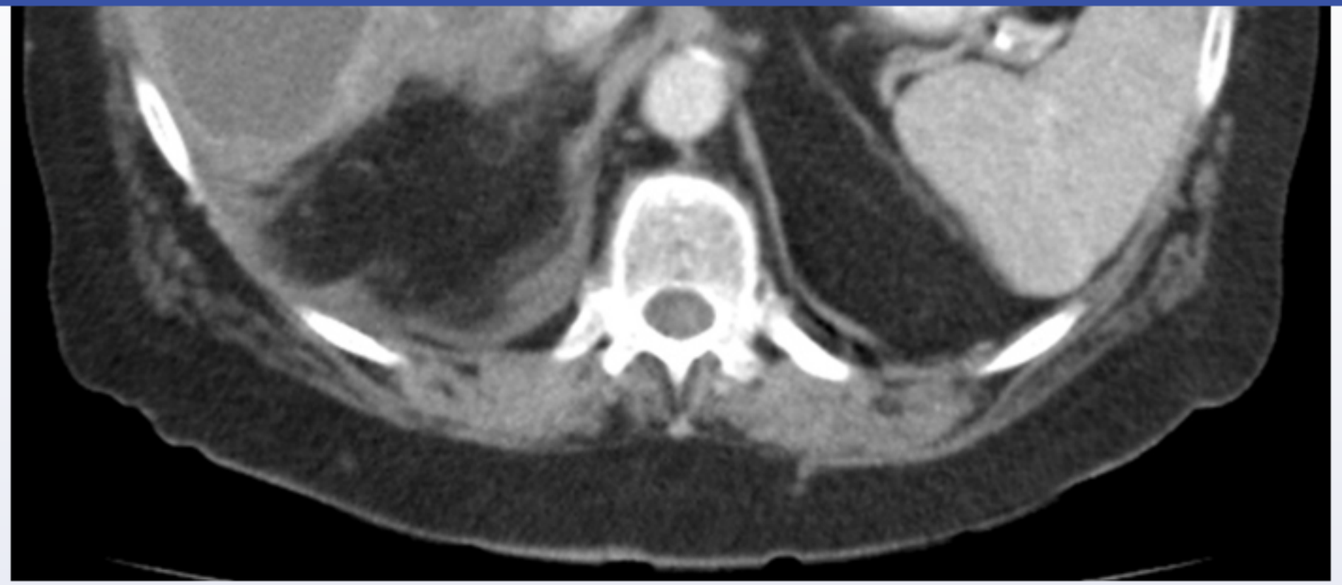

Which of the following microorganism/route combinations is most likely to be the cause of this patient's infection?

- A. *Chlamydia trachomatis* due to ascending cholangitis (7%)
- B. Cytomegalovirus by direct invasion from a nearby source (6%)
- C. *Entamoeba histolytica* due to a penetrating stab wound (37%)
- ✓ D. *Staphylococcus aureus* by hematogenous route (43%)
- E. *Streptococcus pneumoniae* by portal vein (5%)

Omitted
Correct answer

43%
Answered correctly

05 secs
Time Spent

04/12/2020
Last Updated

Settings

1 2 3 4 5 6 7 8 9 10 11 12 13 14 15 16 17 18 19 20 21 22 23 24 25 26 27 28 29 30

Item 24 of 38
Question Id: 62

Mark | Previous | Next | Full Screen | Tutorial | Lab Values | Notes | Calculator | Reverse Color | Text Zoom | Settings

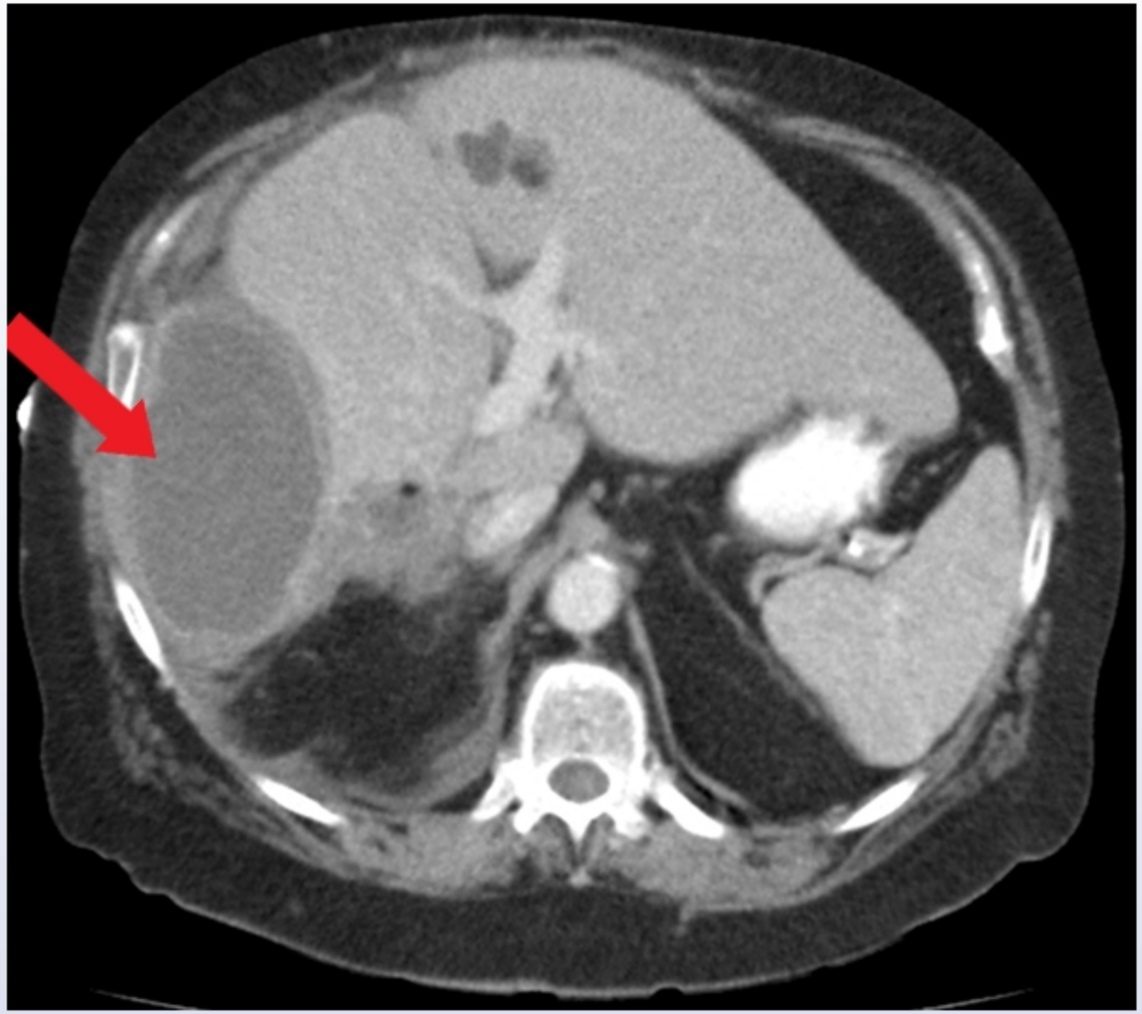

The presence of a **fluid-filled cavity** in the liver in conjunction with fevers, chills, and right upper abdominal pain is suggestive of a **hepatic abscess**. In developing countries, hepatic abscesses have a relatively high incidence and are usually caused by parasitic infections (eg, *Entamoeba histolytica*, echinococcal). In contrast, hepatic abscesses are uncommon in the United States and are caused by **bacterial infection**

Block Time Remaining: 00:00:49
TUTOR

3 | Feedback | Suspend | End Block

The presence of a **fluid-filled cavity** in the liver in conjunction with fevers, chills, and right upper abdominal pain is suggestive of a **hepatic abscess**. In developing countries, hepatic abscesses have a relatively high incidence and are usually caused by parasitic infections (eg, *Entamoeba histolytica*, echinococcal). In contrast, hepatic abscesses are uncommon in the United States and are caused by **bacterial infection** in about 80% of cases.

Pyogenic bacteria can gain access to the liver through the following routes:

- **Biliary tract infection** (eg, ascending cholangitis)
- **Portal vein pyemia** (bowel or peritoneal sources)
- Hepatic artery (systemic hematogenous seeding)
- Direct invasion from an adjacent source (eg, peritonitis, cholecystitis)
- Penetrating trauma or injury

The types of organisms causing a hepatic abscess depend on the route of hepatic access. Systemic **hematogenous seeding** of the liver secondary to ***Staphylococcus aureus*** infection at a distant site is the most plausible choice of all the answer options.

(Choice A) Ascending cholangitis is usually caused by enteric gram-negative bacilli (eg, *Escherichia coli*, *Klebsiella*) and enterococci. *Chlamydia trachomatis* is transmitted sexually and is not found in the enteric environment.

(Choice B) Hepatic abscesses that arise by direct invasion from a nearby source are usually enteric gram-negative bacilli and enterococci. Cytomegalovirus can cause hepatitis in the immunosuppressed patient, but it is not associated with the development of a hepatic abscess.

(Choice C) Traumatic penetrating injuries to the abdomen (eg, stab wound) typically result in abscesses that contain mixed aerobic and anaerobic flora. *Entamoeba histolytica* is most often transmitted through foodborne exposure and in areas with poor sanitation. It can cause a hepatic abscess by ascending from the colon through the portal venous system.

(Choice E) *Streptococcus pneumoniae* colonizes the nasopharynx and typically causes disease within the respiratory tract region (eg, pneumonia, otitis media, sinusitis) and meningitis. However, hepatic abscesses due to portal vein seeding typically arise from abdominal infectious processes (eg, appendicitis, diverticulitis) and *S pneumoniae* is not an enteric pathogen.

- Hepatic artery (systemic hematogenous seeding)
- Direct invasion from an adjacent source (eg, peritonitis, cholecystitis)
- Penetrating trauma or injury

The types of organisms causing a hepatic abscess depend on the route of hepatic access. Systemic **hematogenous seeding** of the liver secondary to ***Staphylococcus aureus*** infection at a distant site is the most plausible choice of all the answer options.

(Choice A) Ascending cholangitis is usually caused by enteric gram-negative bacilli (eg, *Escherichia coli*, *Klebsiella*) and enterococci. *Chlamydia trachomatis* is transmitted sexually and is not found in the enteric environment.

(Choice B) Hepatic abscesses that arise by direct invasion from a nearby source are usually enteric gram-negative bacilli and enterococci. Cytomegalovirus can cause hepatitis in the immunosuppressed patient, but it is not associated with the development of a hepatic abscess.

(Choice C) Traumatic penetrating injuries to the abdomen (eg, stab wound) typically result in abscesses that contain mixed aerobic and anaerobic flora. *Entamoeba histolytica* is most often transmitted through foodborne exposure and in areas with poor sanitation. It can cause a hepatic abscess by ascending from the colon through the portal venous system.

(Choice E) *Streptococcus pneumoniae* colonizes the nasopharynx and typically causes disease within the respiratory tract region (eg, pneumonia, otitis media, sinusitis) and meningitis. However, hepatic abscesses due to portal vein seeding typically arise from abdominal infectious processes (eg, appendicitis, diverticulitis) and *S pneumoniae* is not an enteric pathogen.

Educational objective:
Staphylococcus aureus can cause hepatic abscesses via hematogenous seeding of the liver. Enteric bacteria (eg, *Escherichia coli*, *Klebsiella*, and enterococci) can cause hepatic abscesses by ascending the biliary tract (ie, ascending cholangitis), portal vein pyemia, or direct invasion from an adjacent area (eg, cholecystitis).

Microbiology	Gastrointestinal & Nutrition	Liver abscess
Subject	System	Topic

Copyright © UWorld. All rights reserved.

A 36-year-old man is admitted to the hospital with severe left leg pain after suffering a minor laceration to his leg 2 days earlier. His temperature is 39.5 C (103 F) and blood pressure is 85/45 mm Hg. On physical examination, the patient's left leg is swollen and firm with erythema of the overlying skin. There is a small wound draining blood-tinged exudate on his left calf. The patient is taken to the operating room immediately and a large area of necrotic tissue is excised. Gram stain of the necrotic tissue shows Gram-positive cocci and culture of the bacteria performed on a blood agar plate grows small colonies with a wide zone of surrounding hemolysis. Coagulase and catalase tests are negative and pyrrolidonyl arylamidase (PYR) test is positive. Which of the following pathogens is most likely responsible for this patient's condition?

A. *Aeromonas hydrophila*

B. *Clostridium perfringens*

C. *Staphylococcus aureus*

D. *Streptococcus agalactiae*

E. *Streptococcus pyogenes*

Submit

A 36-year-old man is admitted to the hospital with severe left leg pain after suffering a minor laceration to his leg 2 days earlier. His temperature is 39.5 C (103 F) and blood pressure is 85/45 mm Hg. On physical examination, the patient's left leg is swollen and firm with erythema of the overlying skin. There is a small wound draining blood-tinged exudate on his left calf. The patient is taken to the operating room immediately and a large area of necrotic tissue is excised. Gram stain of the necrotic tissue shows Gram-positive cocci and culture of the bacteria performed on a blood agar plate grows small colonies with a wide zone of surrounding hemolysis. Coagulase and catalase tests are negative and pyrrolidonyl arylamidase (PYR) test is positive. Which of the following pathogens is most likely responsible for this patient's condition?

A. *Aeromonas hydrophila* (1%)

B. *Clostridium perfringens* (19%)

C. *Staphylococcus aureus* (2%)

D. *Streptococcus agalactiae* (6%)

✓ E. *Streptococcus pyogenes* (70%)

Omitted
Correct answer
E

70%
Answered correctly

01 sec
Time Spent

03/13/2020
Last Updated

Explanation

Features of necrotizing fasciitis	

1 2 3 4 5 6 7 8 9 10 11 12 13 14 15 16 17 18 19 20 21 22 23 24 25 26 27 28 29 30

Features of necrotizing fasciitis	
Microbiology	• *Streptococcus pyogenes* (group A streptococci) • *Staphylococcus aureus* • *Clostridium perfringens* • Polymicrobial
Pathogenesis	• Bacteria spread rapidly through subcutaneous tissue & deep fascia, undermining the skin • Most commonly involves extremities & perineal region
Clinical manifestations	• Often antecedent history of minor trauma • Erythema of overlying skin • Swelling & edema • Pain **out of proportion** to examination findings • Systemic symptoms (eg, **fever & hypotension**)
Treatment	• Requires **surgical debridement** & broad-spectrum antibiotics

©UWorld

This patient has necrotizing fasciitis ("flesh-eating disease"), a severe soft-tissue infection characterized by fulminant tissue necrosis and high mortality. The microbiologic differential for this condition includes ***Streptococcus pyogenes, Staphylococcus aureus, Clostridium perfringens***, *Streptococcus agalactiae*, and *Aeromonas hydrophila*. Of these options, *S pyogenes* (group A strep) is the only Gram-positive cocci that is coagulase-negative, catalase-negative, and pyrrolidonyl arylamidase (PYR)-positive. It also forms small colonies with a wide zone of beta-

This patient has necrotizing fasciitis ("flesh-eating disease"), a severe soft-tissue infection characterized by fulminant tissue necrosis and high mortality. The microbiologic differential for this condition includes ***Streptococcus pyogenes, Staphylococcus aureus, Clostridium perfringens***, *Streptococcus agalactiae*, and *Aeromonas hydrophila*. Of these options, *S pyogenes* (group A strep) is the only Gram-positive cocci that is coagulase-negative, catalase-negative, and pyrrolidonyl arylamidase (PYR)-positive. It also forms small colonies with a wide zone of beta-hemolysis and is sensitive to bacitracin (which has been widely replaced by the PYR test).

S pyogenes can be transmitted through wounds and spreads rapidly to the deep layers of the skin and fascia due to production of hyaluronidase and other hydrolytic enzymes. M protein is another major virulence factor that allows the bacteria to evade phagocytosis by preventing activation of the alternate complement pathway. The bacterium also secretes a multitude of extracellular toxins, including hemolysins O and S (cytotoxins that cause hemolysis) and pyrogenic exotoxins (superantigens that result in tissue injury and septic shock).

Typically, there is a sudden onset of **severe pain** and swelling at a site of trauma or recent surgery. Patients quickly become **hypotensive** and develop septic shock. Necrotizing fasciitis is initially treated with **aggressive surgical debridement** of all necrotic tissue along with empiric broad-spectrum antibiotics due to the high incidence of polymicrobial infection.

(Choice A) *A hydrophila* is an oxidase-positive, non-lactose-fermenting, Gram-negative rod. It can cause gastroenteritis, wound infections, and bacteremia following exposure to contaminated water.

(Choice B) *C perfringens* is a large, spore-forming, anaerobic, Gram-positive rod that is catalase- and coagulase-negative. It is implicated in food poisoning, clostridial myonecrosis (gas gangrene), and bacteremia. On blood agar, it produces a double zone of beta-hemolysis.

(Choice C) *S aureus* is Gram-positive coccus that grows in clusters. It is catalase-positive, coagulase-positive, and PYR-negative. *S aureus* produces large colonies and demonstrates beta-hemolysis. Like *S pyogenes*, *S aureus* can also cause monomicrobial necrotizing fasciitis.

(Choice D) *S agalactiae* (group B strep) is a coagulase- and catalase-negative, Gram-positive cocci that grows in chains. Colonies produce a narrow zone of beta-hemolysis that enhances when plated perpendicular to *S aureus* (positive CAMP test). *S agalactiae* can cause skin and soft-tissue infections as well as **newborn sepsis and meningitis**.

Educational objective:
Necrotizing fasciitis is a severe infection of the subcutaneous tissue and deep fascia that is a surgical emergency. The infection is often polymicrobial, but monomicrobial cases due to *Streptococcus pyogenes* (group A strep) can also occur. *S pyogenes* is a **pyrrolidonyl**

and other hydrolytic enzymes. M protein is another major virulence factor that allows the bacteria to evade phagocytosis by preventing activation of the alternate complement pathway. The bacterium also secretes a multitude of extracellular toxins, including hemolysins O and S (cytotoxins that cause hemolysis) and pyrogenic exotoxins (superantigens that result in tissue injury and septic shock).

Typically, there is a sudden onset of **severe pain** and swelling at a site of trauma or recent surgery. Patients quickly become **hypotensive** and develop septic shock. Necrotizing fasciitis is initially treated with **aggressive surgical debridement** of all necrotic tissue along with empiric broad-spectrum antibiotics due to the high incidence of polymicrobial infection.

(Choice A) *A hydrophila* is an oxidase-positive, non-lactose-fermenting, Gram-negative rod. It can cause gastroenteritis, wound infections, and bacteremia following exposure to contaminated water.

(Choice B) *C perfringens* is a large, spore-forming, anaerobic, Gram-positive rod that is catalase- and coagulase-negative. It is implicated in food poisoning, clostridial myonecrosis (gas gangrene), and bacteremia. On blood agar, it produces a double zone of beta-hemolysis.

(Choice C) *S aureus* is Gram-positive coccus that grows in clusters. It is catalase-positive, coagulase-positive, and PYR-negative. *S aureus* produces large colonies and demonstrates beta-hemolysis. Like *S pyogenes*, *S aureus* can also cause monomicrobial necrotizing fasciitis.

(Choice D) *S agalactiae* (group B strep) is a coagulase- and catalase-negative, Gram-positive cocci that grows in chains. Colonies produce a narrow zone of beta-hemolysis that enhances when plated perpendicular to *S aureus* (positive CAMP test). *S agalactiae* can cause skin and soft-tissue infections as well as **newborn sepsis and meningitis**.

Educational objective:
Necrotizing fasciitis is a severe infection of the subcutaneous tissue and deep fascia that is a surgical emergency. The infection is often polymicrobial, but monomicrobial cases due to *Streptococcus pyogenes* (group A strep) can also occur. *S pyogenes* is a **pyrrolidonyl arylamidase (PYR)-positive**, beta-hemolytic, Gram-positive cocci that grows in chains.

Microbiology	Rheumatology/Orthopedics & Sports	Necrotizing soft tissue infections
Subject	System	Topic

Copyright © UWorld. All rights reserved.

A 52-year-old active smoker comes to the office due to a 2-week history of malaise, shortness of breath, and decreased appetite. The patient has a history of bicuspid aortic valve and hypertension. His temperature is 39 C (102.2 F), blood pressure is 140/80 mm Hg, and pulse is 110/min. On examination, the patient has a systolic ejection murmur at the right upper sternal border that is unchanged from previous visits; there is a new decrescendo diastolic murmur best heard in the third intercostal space at the left sternal border. Laboratory studies show hemoglobin is 9.3 g/dL and leukocytes are 16,500/mm^3. Blood cultures are positive for *Streptococcus gallolyticus* (formerly *S bovis*). Additional workup for this patient should focus on which of the following conditions?

A. Colonic neoplasia

B. Intravenous drug use

C. Lung cancer

D. Oral infection

E. Urinary tract infection

Submit

A 52-year-old active smoker comes to the office due to a 2-week history of malaise, shortness of breath, and decreased appetite. The patient has a history of bicuspid aortic valve and hypertension. His temperature is 39 C (102.2 F), blood pressure is 140/80 mm Hg, and pulse is 110/min. On examination, the patient has a systolic ejection murmur at the right upper sternal border that is unchanged from previous visits; there is a new decrescendo diastolic murmur best heard in the third intercostal space at the left sternal border. Laboratory studies show hemoglobin is 9.3 g/dL and leukocytes are 16,500/mm^3. Blood cultures are positive for *Streptococcus gallolyticus* (formerly *S bovis*). Additional workup for this patient should focus on which of the following conditions?

- ✓ A. Colonic neoplasia (83%)
- B. Intravenous drug use (7%)
- C. Lung cancer (1%)
- D. Oral infection (5%)
- E. Urinary tract infection (1%)

Omitted
Correct answer
A

83%
Answered correctly

02 secs
Time Spent

05/19/2020
Last Updated

Explanation

Streptococcus gallolyticus (formerly *S bovis*) is the main human pathogen among nonenterococcal group D streptococci. It causes a **subacute bacterial endocarditis** (SBE) with symptoms similar to those of *S viridans* SBE. *S gallolyticus* is part of the normal flora of the colon, and bacteremia or endocarditis caused by *S gallolyticus* is associated with **colonic cancer** in ~25% of cases. The relationship between *S gallolyticus* and colon cancer is unclear, but every patient with *S gallolyticus* bacteremia with or without endocarditis should be examined for a gastrointestinal

Omitted
Correct answer
A

83%
Answered correctly

02 secs
Time Spent

05/19/2020
Last Updated

Explanation

Streptococcus gallolyticus (formerly *S bovis*) is the main human pathogen among nonenterococcal group D streptococci. It causes a **subacute bacterial endocarditis** (SBE) with symptoms similar to those of *S viridans* SBE. *S gallolyticus* is part of the normal flora of the colon, and bacteremia or endocarditis caused by *S gallolyticus* is associated with **colonic cancer** in ~25% of cases. The relationship between *S gallolyticus* and colon cancer is unclear, but every patient with *S gallolyticus* bacteremia with or without endocarditis should be examined for a gastrointestinal tract malignancy.

S gallolyticus endocarditis is also unique in that most cases occur in patients without preexisting valvular abnormality.

(Choice B) Right-sided endocarditis commonly occurs in intravenous drug users and is typically caused by *Staphylococcus aureus*.

(Choices C and E) There is no known association between endocarditis and lung cancer. *S gallolyticus* can cause septic shock, meningitis, or joint infection; it does not typically cause urinary tract infections.

(Choice D) *S viridans* is the most common etiologic agent in subacute bacterial endocarditis following dental work.

Educational objective:
Streptococcus gallolyticus (formerly *S bovis*) endocarditis and bacteremia are associated with gastrointestinal lesions (colon cancer) in ~25% of cases. When *S gallolyticus* is cultured in the blood, workup for colonic malignancy with colonoscopy is essential.

Microbiology	Cardiovascular System	Endocarditis
Subject	System	Topic

Copyright © UWorld. All rights reserved.

A 23-year-old man comes to the physician due to a 2-month history of fatigue, malaise, and abdominal discomfort. He is found to have tender hepatomegaly with elevated liver function tests. The patient has never been vaccinated against hepatitis. He has had no raw or uncooked foods recently and recalls no ill contacts. There is no history of blood transfusion. The patient is a graduate student who immigrated to the United States 2 years ago and has not traveled outside the country since. He smokes 2 packs of cigarettes a day and consumes 1 or 2 bottles of beer on weekends. The patient does not use illicit drugs. He has had several episodes of unprotected sex with different female partners within the past year. Which of the following is most likely to be present in this patient?

- A. HAV in the stool
- B. Serum anti-HAV IgM
- C. Serum anti-HBsAg IgG
- D. Serum HBsAg
- E. Hepatitis C virus RNA viral load in blood
- F. Serum anti-hepatitis D virus IgG

Submit

1 2 3 4 5 6 7 8 9 10 11 12 13 14 15 16 17 18 19 20 21 22 23 24 25 26 27 28 29 30

A 23-year-old man comes to the physician due to a 2-month history of fatigue, malaise, and abdominal discomfort. He is found to have tender hepatomegaly with elevated liver function tests. The patient has never been vaccinated against hepatitis. He has had no raw or uncooked foods recently and recalls no ill contacts. There is no history of blood transfusion. The patient is a graduate student who immigrated to the United States 2 years ago and has not traveled outside the country since. He smokes 2 packs of cigarettes a day and consumes 1 or 2 bottles of beer on weekends. The patient does not use illicit drugs. He has had several episodes of unprotected sex with different female partners within the past year. Which of the following is most likely to be present in this patient?

- A. HAV in the stool (0%)
- B. Serum anti-HAV IgM (1%)
- C. Serum anti-HBsAg IgG (7%)
- ✓ D. Serum HBsAg (79%)
- E. Hepatitis C virus RNA viral load in blood (10%)
- F. Serum anti-hepatitis D virus IgG (0%)

Omitted
Correct answer
D

79%
Answered correctly

02 secs
Time Spent

03/31/2020
Last Updated

Explanation

The main modes of transmission of **hepatitis B virus (HBV)** are sexual (transmission among heterosexual partners and among men who have sex with men) and percutaneous (eg, intravenous drug use, needlestick accidents, blood transfusions). Vertical (mother-to-child) transmission is

The main modes of transmission of **hepatitis B virus (HBV)** are sexual (transmission among heterosexual partners and among men who have sex with men) and percutaneous (eg, intravenous drug use, needlestick accidents, blood transfusions). Vertical (mother-to-child) transmission is common in high-prevalence areas. This **unvaccinated** patient with tender hepatomegaly and liver function abnormalities most likely has acute HBV infection contracted during an episode of **unprotected sex** (most common mode of transmission in developed countries, >70% of cases). Serum hepatitis B surface antigen (HBsAg) would be present.

Anti-HBsAg immunoglobulin G (IgG) appears after either successful HBV vaccination or HBsAg clearance and remains detectable for life (indicator of non-infectivity and immunity). Because this patient is symptomatic, he obviously has not cleared the virus and would likely not yet have anti-HBsAg IgG **(Choice C)**.

(Choices A and B) Hepatitis A virus (HAV) in the stool or serum anti-HAV IgM would be expected with acute HAV following recent travel to an endemic area or consumption of tainted, insufficiently heated food (eg, oysters). HAV (fecal-oral transmission) is not usually symptomatic for 2 months and is not associated with a chronic carrier state.

(Choice E) Hepatitis C virus (HCV) infection is most often asymptomatic. Also, most HCV transmission occurs in the setting of intravenous drug use. Sexual transmission of HCV can occur but is inefficient; the risk is actually low (eg, incidence of 0.07% per year in a study of 500 heterosexual couples) and would be lower than that of HBV transmission.

(Choice F) Hepatitis D virus (HDV) transmission occurs primarily through inoculations and blood transfusions, with sexual transmission far less common. Co-infection with HBV or superinfection of chronic HBV is necessary. Globally, only about 5% of HBV carriers also have HDV (rates vary based on geography).

Educational objective:
The main modes of transmission of hepatitis B virus include sexual (among both heterosexual partners and men who have sex with men) and percutaneous (eg, intravenous drug use, needlestick accidents, blood transfusions). The risk of sexual transmission of hepatitis C virus is low.

Microbiology	Gastrointestinal & Nutrition	Hepatitis b
Subject	System	Topic

A 46-year-old HIV-positive man is hospitalized with fever, cramping abdominal pain, and watery diarrhea. Evaluation shows high fever, hypotension, tachycardia, and lower abdominal distension and tenderness. Abdominal x-ray reveals free intraperitoneal air, and the patient is taken for urgent exploratory laparotomy. Operative findings include an erythematous and dilated colon. A focus of bowel wall necrosis with perforation is resected. Histopathology reveals acute inflammatory changes and epithelial necrosis as shown below.

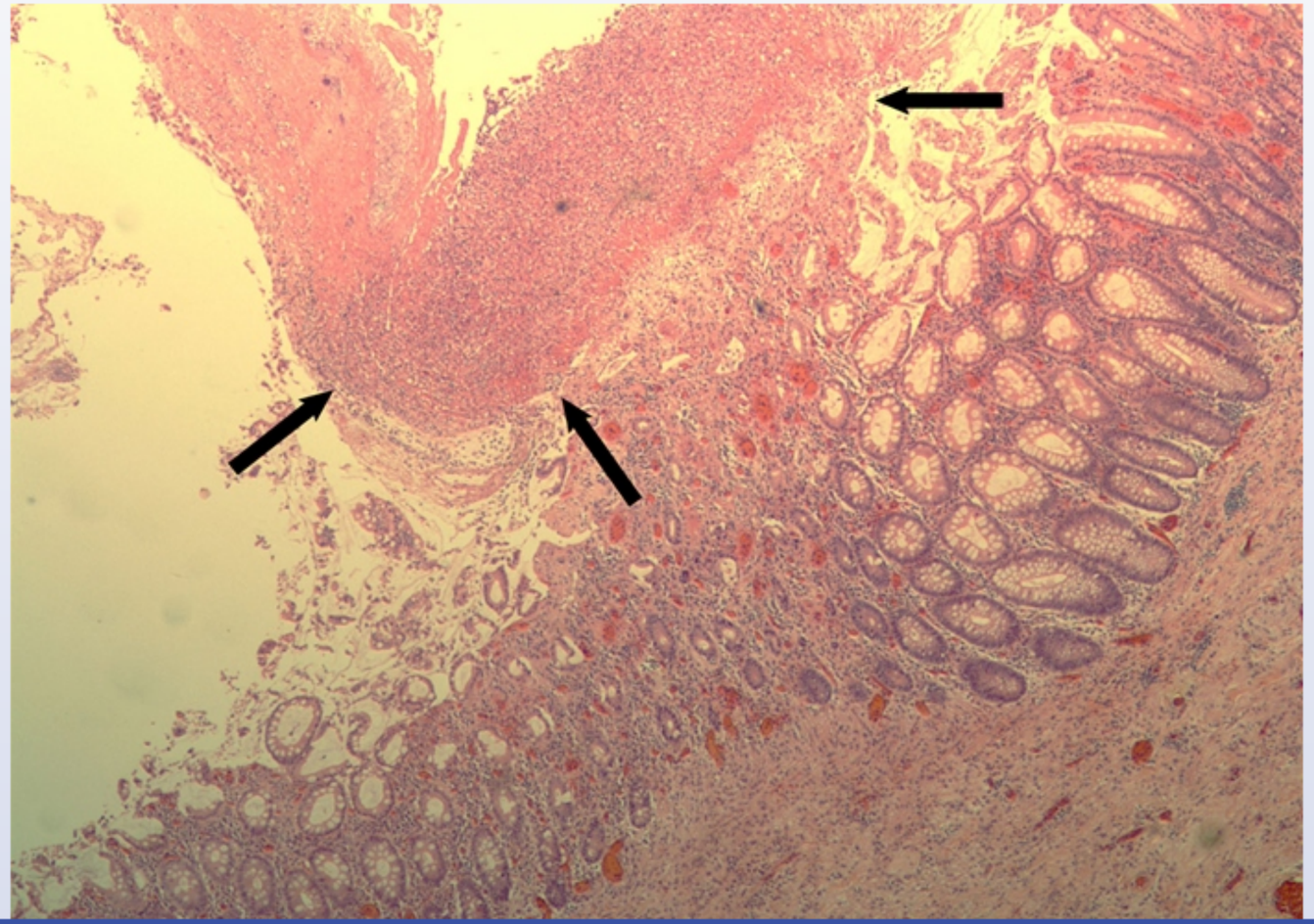

1 2 3 4 5 6 7 8 9 10 11 12 13 14 15 16 17 18 19 20 21 22 23 24 25 26 27 28 29 30

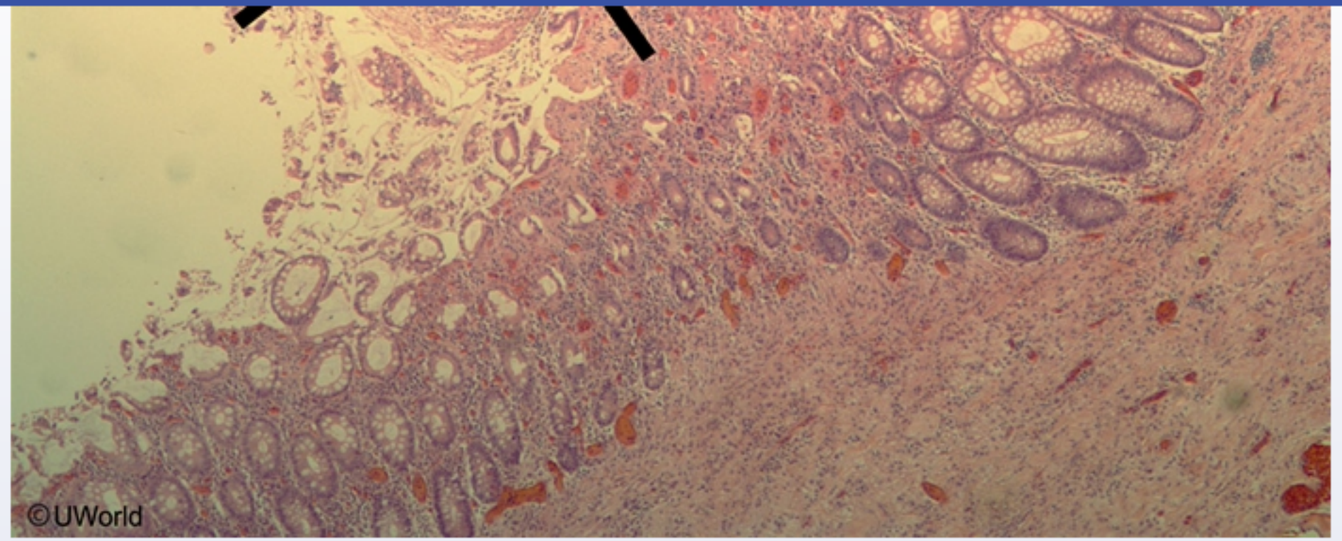

There is a layer of denuded epithelium, fibrin, and inflammatory cells overlaying the mucosa (see arrows). Which of the following is the most likely responsible pathogen?

- A. *Campylobacter jejuni*
- B. *Clostridium difficile*
- C. *Salmonella typhi*
- D. *Shigella flexneri*
- E. *Vibrio cholerae*

Submit

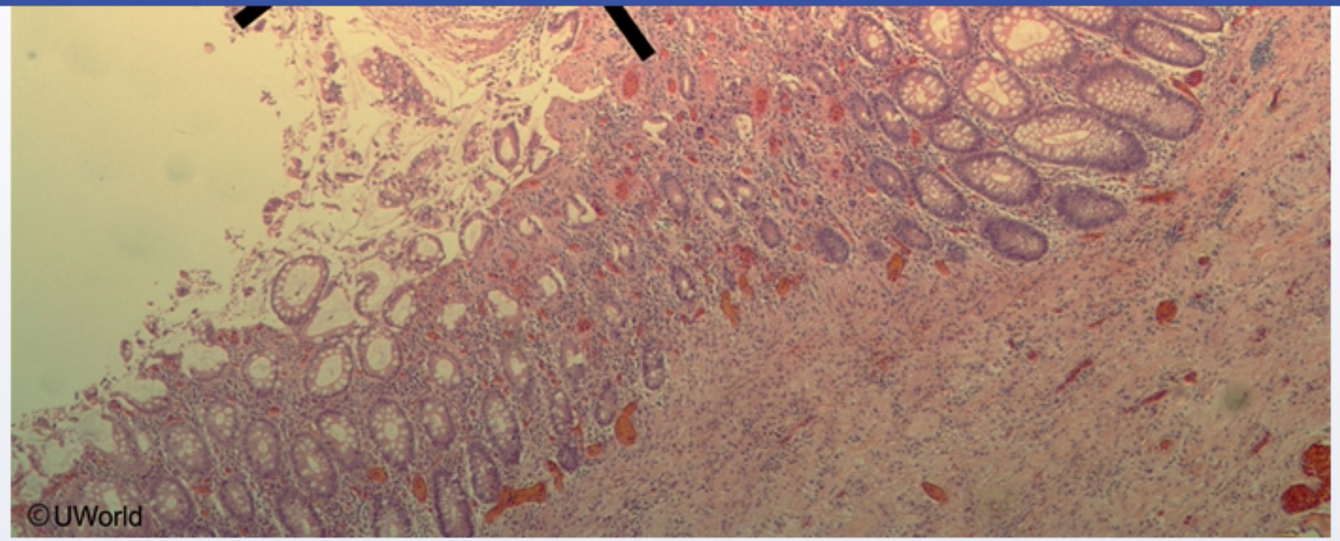

There is a layer of denuded epithelium, fibrin, and inflammatory cells overlaying the mucosa (see arrows). Which of the following is the most likely responsible pathogen?

- A. *Campylobacter jejuni* (6%)
- ✓ B. *Clostridium difficile* (64%)
- C. *Salmonella typhi* (11%)
- D. *Shigella flexneri* (9%)
- E. *Vibrio cholerae* (7%)

Omitted
Correct answer

64%
Answered correctly

05 secs
Time Spent

02/15/2020
Last Updated

This patient with diarrhea, abdominal pain, and fever developed a colonic perforation. In conjunction with the pseudomembrane demonstrated on histology, this presentation is highly suggestive of ***Clostridium difficile* infection** (CDI). *C difficile* is an anaerobic, spore-forming, toxigenic, gram-positive rod that causes infectious colitis. The most significant risk factor for the development of CDI is antibiotic use. Antibiotics (particularly clindamycin, fluoroquinolones, and cephalosporins) alter the normal bowel flora, thereby predisposing to *C difficile* overgrowth. Other risk factors include hospitalization, older age, and proton pump inhibitor use.

C difficile produces 2 toxins: Toxin A (enterotoxin) and Toxin B (cytotoxin). These toxins disrupt cellular cytoskeletons and intercellular tight junctions, leading to colonocyte apoptosis. The colonic mucosa responds to toxin exposure by forming white, patchy pseudomembranes, which consist of a **neutrophil-predominant** inflammatory infiltrate, **fibrin**, bacteria, and necrotic epithelium. Patients with severe disease may develop a nonobstructive colonic dilation known as **toxic megacolon**, which leads to increased risk of colonic perforation (as seen in this patient).

(Choice A) *Campylobacter jejuni* is associated with watery diarrhea that may become bloody, abdominal cramping, and fever. Neutrophilic infiltrate and crypt abscesses are identified on histology.

(Choice C) *Salmonella typhi* causes typhoid fever, which manifests with bloody diarrhea, abdominal pain, high fever, and salmon-colored macules located mainly on the trunk. Histology demonstrates a lymphoplasmacytic inflammatory infiltrate and associated hemorrhage.

(Choice D) *Shigella flexneri* infection is characterized by sudden onset of severe abdominal cramping, bloody diarrhea, vomiting, and high fever. Cryptitis, ulcerations, and crypt abscesses are identified on histology.

(Choice E) *Vibrio cholerae* causes cholera, which manifests with sudden onset, voluminous, "rice water" diarrhea and vomiting. Histology typically remains normal.

Educational objective:
Clostridium difficile infection is associated with white, patchy pseudomembranes on the bowel mucosa. These pseudomembranes consist of a neutrophil-predominant inflammatory infiltrate, fibrin, bacteria, and necrotic epithelium. Patients may develop a nonobstructive colonic dilation known as toxic megacolon, which can lead to colonic perforation.

Microbiology	Gastrointestinal & Nutrition	Clostridium difficile infection
Subject	System	Topic

This patient with diarrhea, abdominal pain, and fever developed a colonic perforation. In conjunction with the pseudomembrane demonstrated on

Exhibit Display

Pseudomembranous colitis

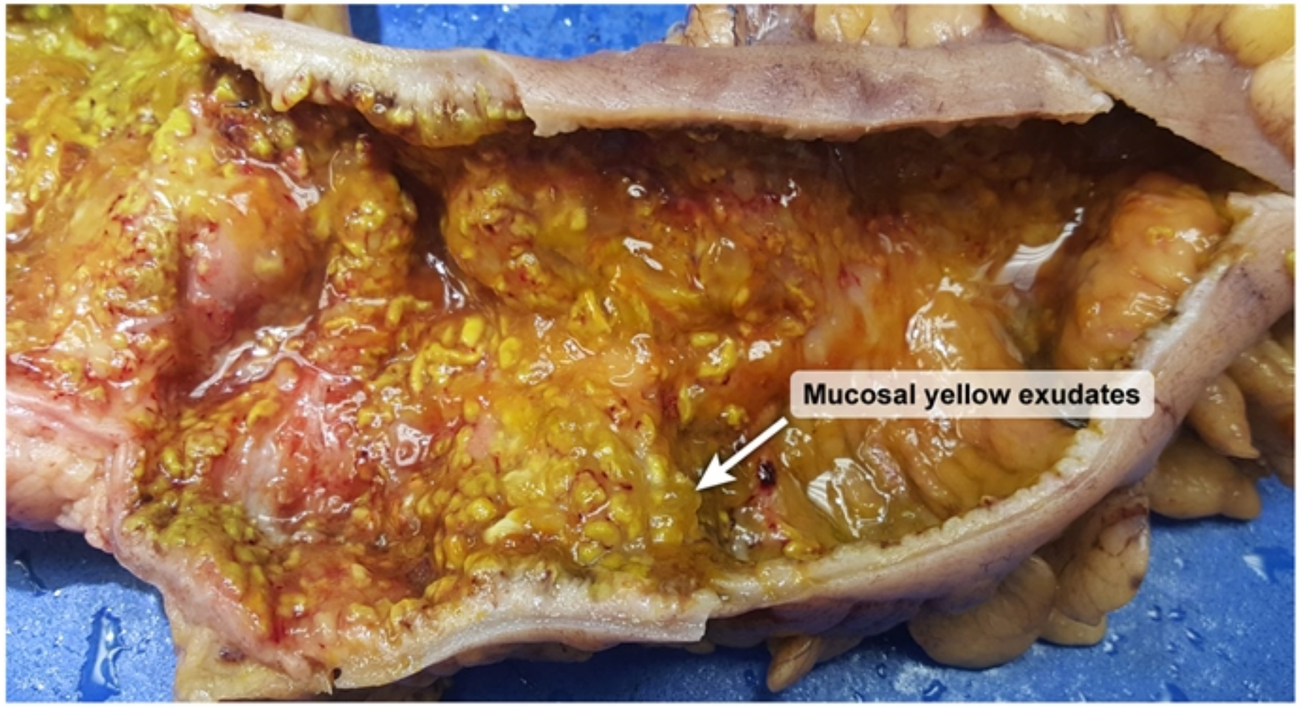

©UWorld

Zoom In | Zoom Out | Reset | Add To New Card | Existing Card

A pharmaceutical researcher is trying to develop a vaccine against the hepatitis C virus. She infects a chimpanzee with hepatitis C virus of known genotype and subtype. Several weeks later, a liver sample is obtained, and viral RNAs are extracted from the hepatocytes. A genetic study of the viral genomes reveals that the extracted RNA sequences vary significantly from that of the original infecting virus. This genetic instability is most likely due to the lack of which of the following features during the viral replication process?

- A. 3' → 5' exonuclease activity
- B. 5' → 3' exonuclease activity
- C. Glycosylase activity
- D. Ligase activity
- E. Nucleotide specificity
- F. Primase activity

Submit

A pharmaceutical researcher is trying to develop a vaccine against the hepatitis C virus. She infects a chimpanzee with hepatitis C virus of known genotype and subtype. Several weeks later, a liver sample is obtained, and viral RNAs are extracted from the hepatocytes. A genetic study of the viral genomes reveals that the extracted RNA sequences vary significantly from that of the original infecting virus. This genetic instability is most likely due to the lack of which of the following features during the viral replication process?

- ✓ A. 3' → 5' exonuclease activity (67%)
- B. 5' → 3' exonuclease activity (20%)
- C. Glycosylase activity (2%)
- D. Ligase activity (2%)
- E. Nucleotide specificity (5%)
- F. Primase activity (2%)

Omitted
Correct answer
A

67%
Answered correctly

02 secs
Time Spent

01/13/2020
Last Updated

Explanation

Hepatitis C virus (HCV) has ≥6 genotypes and multiple subgenotypes. These variant strains differ primarily at **hypervariable** genomic regions, such as those found in the sequences encoding its 2 **envelope glycoproteins**. Moreover, there is **no proofreading 3' → 5'** exonuclease activity built into the virion-encoded RNA polymerase. As a result, the RNA polymerase makes many errors during replication, and several dozen subspecies of HCV are typically present in the blood of an infected individual at any one time.

Explanation

Hepatitis C virus (HCV) has ≥6 genotypes and multiple subgenotypes. These variant strains differ primarily at **hypervariable** genomic regions, such as those found in the sequences encoding its 2 **envelope glycoproteins**. Moreover, there is **no proofreading 3' → 5'** exonuclease activity built into the virion-encoded RNA polymerase. As a result, the RNA polymerase makes many errors during replication, and several dozen subspecies of HCV are typically present in the blood of an infected individual at any one time.

(Choice B) 5' → 3' exonuclease activity allows DNA polymerase I to engage in nick translation, which is important for both DNA repair and removal of RNA primers during replication. This feature is not the cause of instability in HCV.

(Choice C) DNA glycosylase is important in base excision repair as it removes the nitrogen base from the sugar-phosphate backbone. An endonuclease then completes the remainder of the repair. This enzyme is not the cause of instability in HCV.

(Choice D) DNA ligase is used to join 2 fragments of DNA and is therefore necessary for both DNA repair and replication. The HCV genome is a single-stranded, positive-sense RNA molecule that does not require ligase activity during replication.

(Choice E) Nucleotide specificity refers to the importance of inserting the correct nucleotide (eg, adenine, guanine, cytosine, thymine, uracil) into a strand of DNA or RNA. It is not the cause of instability in HCV.

(Choice F) DNA primase is a form of RNA polymerase. In bacteria, it binds with DNA helicase and synthesizes a short RNA primer to which nucleotides can be added by DNA polymerase. This enzyme is not the cause of instability in HCV.

Educational objective:
The hepatitis C virus is genetically unstable because it lacks proofreading 3' → 5' exonuclease activity in its RNA polymerase. Its envelope glycoprotein sequences also contain a hypervariable region prone to frequent genetic mutation.

Microbiology	Gastrointestinal & Nutrition	Hepatitis c
Subject	System	Topic

Copyright © UWorld. All rights reserved.

A 65-year-old man comes to the office after his wife insisted he get a checkup. The patient feels well and has no chronic medical conditions but has not seen a physician in many years. He received blood transfusions after a motor vehicle trauma in his 20s. The patient does not use tobacco or illicit drugs but drinks 2 or 3 alcoholic beverages daily. Physical examination reveals no hepatomegaly, ascites, or dilation of the superficial abdominal veins. The remainder of the examination shows no abnormalities. Serology is positive for hepatitis C antibodies. Chronic hepatitis C infection is confirmed with positive HCV RNA testing. After appropriate counseling is provided, combination therapy with sofosbuvir and ledipasvir is planned. This treatment is most likely to help clear the infection through which of the following mechanisms?

- A. Blocking reverse transcription of viral RNA
- B. Enhancing antiviral host immune response
- C. Impairing viral entry into host cells
- D. Inhibiting viral genome replication and assembly
- E. Preventing new virion release from infected host cells

Submit

A 65-year-old man comes to the office after his wife insisted he get a checkup. The patient feels well and has no chronic medical conditions but has not seen a physician in many years. He received blood transfusions after a motor vehicle trauma in his 20s. The patient does not use tobacco or illicit drugs but drinks 2 or 3 alcoholic beverages daily. Physical examination reveals no hepatomegaly, ascites, or dilation of the superficial abdominal veins. The remainder of the examination shows no abnormalities. Serology is positive for hepatitis C antibodies. Chronic hepatitis C infection is confirmed with positive HCV RNA testing. After appropriate counseling is provided, combination therapy with sofosbuvir and ledipasvir is planned. This treatment is most likely to help clear the infection through which of the following mechanisms?

A. Blocking reverse transcription of viral RNA (16%)

B. Enhancing antiviral host immune response (3%)

C. Impairing viral entry into host cells (3%)

✓ D. Inhibiting viral genome replication and assembly (66%)

E. Preventing new virion release from infected host cells (10%)

Omitted
Correct answer
D

66%
Answered correctly

02 secs
Time Spent

01/29/2020
Last Updated

Explanation

Hepatitis C virus (HCV) is a blood-borne pathogen that is primarily transmitted via injection drug use or transfusion of blood products (prior to widespread screening in 1992). Chronic infection develops in most individuals and increases the risk for cirrhosis and hepatocellular carcinoma. Because chronic HCV infection is often asymptomatic for decades, patients are often unaware that they have contracted the virus. Therefore, HCV testing is recommended for high-risk patients (eg, remote history of blood transfusion)

Hepatitis C virus (HCV) is a blood-borne pathogen that is primarily transmitted via injection drug use or transfusion of blood products (prior to widespread screening in 1992). Chronic infection develops in most individuals and increases the risk for cirrhosis and hepatocellular carcinoma. Because chronic HCV infection is often asymptomatic for decades, patients are often unaware that they have contracted the virus. Therefore, HCV testing is recommended for high-risk patients (eg, remote history of blood transfusion).

Treatment of chronic HCV infection is with direct-acting antiviral (DAA) agents, which target specific enzymes in the HCV life cycle to **inhibit viral replication and assembly**, as follows:

- **RNA-dependent RNA polymerase inhibitors** – HCV binds to and enters host cells, uncoats, and subsequently replicates its genome using HCV-encoded RNA-dependent RNA polymerase. Nucleotide/non-nucleoside RNA polymerase inhibitors such as **sofosbuvir** target this step.
- **Protease inhibitors** – HCV mRNA is translated by host ribosomes into a polyprotein, which is cleaved by HCV protease into the individual proteins that compose the virus. HCV protease inhibitors such as simeprevir target this step.
- **NS5A inhibitors** – The HCV protein NS5A is crucial for viral replication and assembly (through unclear mechanisms) and is targeted by HCV medications such as **ledipasvir**.

DAA treatment results in a sustained virologic response (complete elimination of virus) in >97% of treated individuals.

(Choice A) HCV does not contain a reverse transcriptase enzyme so it does not integrate its genome into the host cell. Therefore, there are no reverse transcriptase inhibitors for HCV. Reverse transcriptase inhibitors are a mainstay of therapy for HIV.

(Choice B) Interferon-gamma was previously used in the treatment of chronic HCV (in combination with ribavirin) to trigger a broad antiviral immune response. However, interferon therapy has a lower cure rate (50%-80%) and a much higher incidence of side effects (eg, flu-like symptoms). Therefore, DAAs are now used preferentially.

(Choice C) HIV fusion inhibitors (eg, enfuvirtide) and CCR5 inhibitors (eg, maraviroc) inhibit the ability of HIV to enter cells. DAAs do not target viral entry.

(Choice E) Although HCV virion release could be a target for DAAs, there are currently no approved medications that target this step. Virion

HCV medications such as **ledipasvir**.

DAA treatment results in a sustained virologic response (complete elimination of virus) in >97% of treated individuals.

(Choice A) HCV does not contain a reverse transcriptase enzyme so it does not integrate its genome into the host cell. Therefore, there are no reverse transcriptase inhibitors for HCV. Reverse transcriptase inhibitors are a mainstay of therapy for HIV.

(Choice B) Interferon-gamma was previously used in the treatment of chronic HCV (in combination with ribavirin) to trigger a broad antiviral immune response. However, interferon therapy has a lower cure rate (50%-80%) and a much higher incidence of side effects (eg, flu-like symptoms). Therefore, DAAs are now used preferentially.

(Choice C) HIV fusion inhibitors (eg, enfuvirtide) and CCR5 inhibitors (eg, maraviroc) inhibit the ability of HIV to enter cells. DAAs do not target viral entry.

(Choice E) Although HCV virion release could be a target for DAAs, there are currently no approved medications that target this step. Virion release (budding) is targeted by neuraminidase inhibitors in the treatment of influenza.

Educational objective:
Chronic hepatitis C virus infection is treated with direct-acting antiviral (DAAs) medications such as ledipasvir and sofosbuvir. These medications target specific HCV enzymes (eg, protease, NS5A, RNA polymerase), which inhibits viral replication and assembly. Treatment with DAAs results in cure in >97% of patients.

References

- HCV NS5A replication complex inhibitors.
- Virology and cell biology of the hepatitis C virus life cycle: an update.

Microbiology	Gastrointestinal & Nutrition	Hepatitis c
Subject	System	Topic

Copyright © UWorld. All rights reserved.

HCV medications such as **ledipasvir**.

Exhibit Display

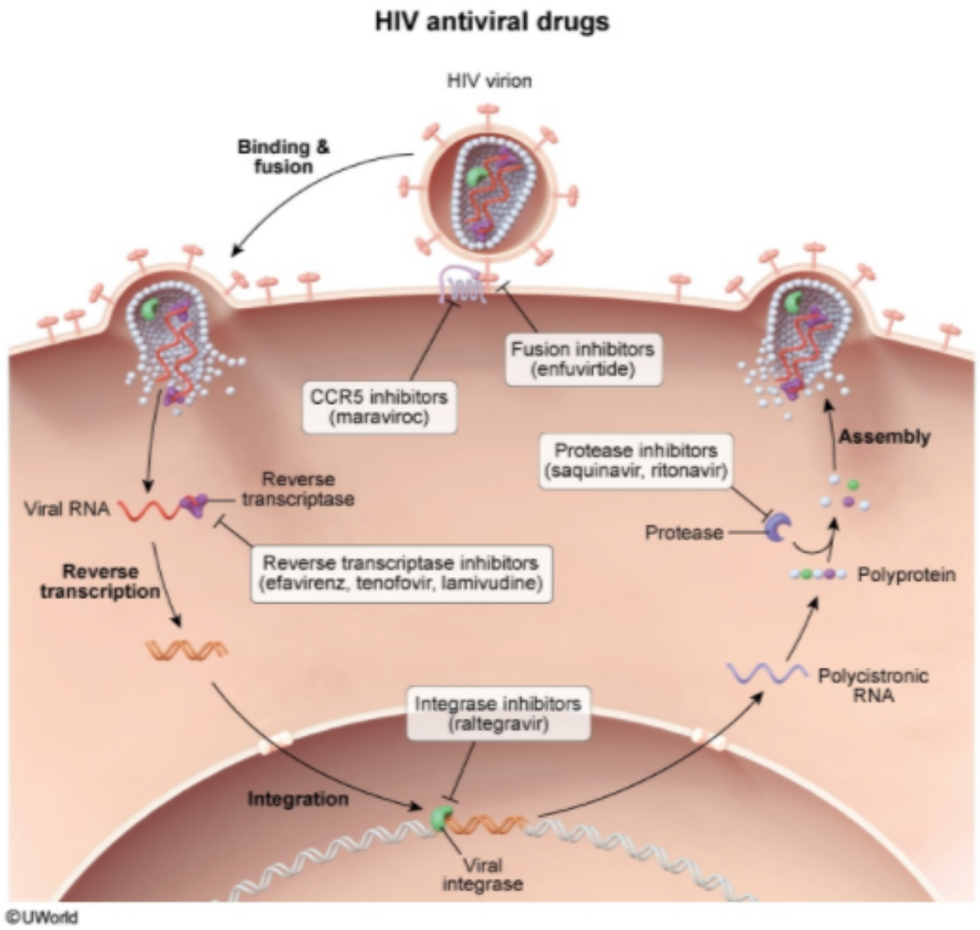

Zoom In | Zoom Out | Reset | Add To New Card | Existing Card

A 22-year-old woman comes to the emergency department due to intermittent fevers and chills over the past few days. Last week, she underwent routine dental cleaning with no complications. The patient has a history of mitral valve prolapse. Temperature is 38.2 C (100.8 F). Physical examination reveals a non-ejection mid-systolic click followed by a late-systolic murmur best heard at the cardiac apex. Blood cultures are drawn and grow gram-positive bacteria that synthesize dextrans from sucrose. Which of the following would be the most likely adherence site for these bacteria?

A. Circulating heparins

B. Endothelial surface glycoproteins

C. Fibrin-platelet aggregates

D. Subendothelial collagen

E. Subendothelial glycosaminoglycans

Submit

A 22-year-old woman comes to the emergency department due to intermittent fevers and chills over the past few days. Last week, she underwent routine dental cleaning with no complications. The patient has a history of mitral valve prolapse. Temperature is 38.2 C (100.8 F). Physical examination reveals a non-ejection mid-systolic click followed by a late-systolic murmur best heard at the cardiac apex. Blood cultures are drawn and grow gram-positive bacteria that synthesize dextrans from sucrose. Which of the following would be the most likely adherence site for these bacteria?

- A. Circulating heparins (0%)
- B. Endothelial surface glycoproteins (24%)
- ✓ C. Fibrin-platelet aggregates (53%)
- D. Subendothelial collagen (10%)
- E. Subendothelial glycosaminoglycans (11%)

Omitted
Correct answer
C

53%
Answered correctly

02 secs
Time Spent

05/18/2020
Last Updated

Explanation

This patient with mitral valve prolapse (as suggested by the auscultated systolic click and murmur) now has bacteremia following dental cleaning. **Viridans streptococci** are normal inhabitants of the oral cavity and cause **transient bacteremia** after **dental** procedures. These gram-positive organisms are capable of producing extracellular polysaccharides (**dextrans**) using sucrose as a substrate.

Dextrans facilitate streptococcal adherence to fibrin. **Fibrin and platelets** are deposited at sites of endothelial trauma, providing a site for

This patient with mitral valve prolapse (as suggested by the auscultated systolic click and murmur) now has bacteremia following dental cleaning. **Viridans streptococci** are normal inhabitants of the oral cavity and cause **transient bacteremia** after **dental** procedures. These gram-positive organisms are capable of producing extracellular polysaccharides (**dextrans**) using sucrose as a substrate.

Dextrans facilitate streptococcal adherence to fibrin. **Fibrin and platelets** are deposited at sites of endothelial trauma, providing a site for bacterial adherence and colonization during bacteremia. In patients with pre-existing valvular lesions, viridans streptococci can adhere to the affected valve and establish infection leading to endocarditis. Other factors that facilitate pathogenesis may also be involved. *Staphylococcus aureus* is more aggressive and can adhere to intact valves. The risk of endocarditis following dental procedures is low with mitral valve prolapse, and antibiotic prophylaxis is not recommended; however, cases can still occur.

(Choice A) Circulating heparins prolong the partial thromboplastin time by activating antithrombin III, thereby decreasing thrombin activity and ultimately preventing fibrinogen conversion to fibrin, thereby preventing clot formation. Circulating heparins would not provide a binding site for bacteria.

(Choice B) Endothelial surface glycoproteins mediate binding of immune cells to endothelium, facilitated by the expression of cell adhesion molecules on the surface of inflamed endothelium. Neutrophils are then able to bind and migrate between the endothelial cells, followed by monocytes and lymphocytes.

(Choices D and E) Subendothelial collagen and glycosaminoglycans form the subendothelial fibrous cap over the central core of an atherosclerotic plaque and are potent platelet activators. When exposed (eg, denuded endothelium in atherosclerotic plaque), they contribute to rapid thrombus formation that can lead to myocardial infarction in a coronary artery.

Educational objective:
Viridans streptococci are normal inhabitants of the oral cavity and are a cause of transient bacteremia after dental procedures in healthy and diseased individuals. In patients with pre-existing valvular lesions, viridans streptococci can adhere to fibrin-platelet aggregates and establish infection that leads to endocarditis.

Microbiology	Cardiovascular System	Endocarditis
Subject	System	Topic

A 34-year-old immigrant from southern Asia complains of intermittent abdominal cramps. He has had multiple respiratory infections over the last 2 years as well as a persistent, chronic cough. Laboratory results are as follows:

Complete blood count	
Hemoglobin	13.0 g/dL
Leukocytes	6,800 cells/μL
Neutrophils	56%
Eosinophils	14%
Lymphocytes	26%
Monocytes	4%

Which of the following findings in this patient would be most suggestive of *Strongyloides stercoralis* infection?

- A. Parasite eggs in the stool
- B. Perianal egg deposition
- C. Proglottids in the stool
- D. Rhabditiform larvae in the stool
- E. Trophozoites and cysts in the stool

Submit

A 34-year-old immigrant from southern Asia complains of intermittent abdominal cramps. He has had multiple respiratory infections over the last 2 years as well as a persistent, chronic cough. Laboratory results are as follows:

Complete blood count	
Hemoglobin	13.0 g/dL
Leukocytes	6,800 cells/μL
Neutrophils	56%
Eosinophils	14%
Lymphocytes	26%
Monocytes	4%

Which of the following findings in this patient would be most suggestive of *Strongyloides stercoralis* infection?

A. Parasite eggs in the stool (33%)
B. Perianal egg deposition (6%)
C. Proglottids in the stool (11%)
✓ D. Rhabditiform larvae in the stool (34%)
E. Trophozoites and cysts in the stool (13%)

Omitted
Correct answer
34%
02 secs
04/10/2020

Settings

1 2 3 4 5 6 7 8 9 10 11 12 13 14 15 16 17 18 19 20 21 22 23 24 25 26 27 28 29 30

Item 32 of 38
Question Id: 8873

Mark | Previous | Next | Full Screen | Tutorial | Lab Values | Notes | Calculator | Reverse Color | Text Zoom | Settings

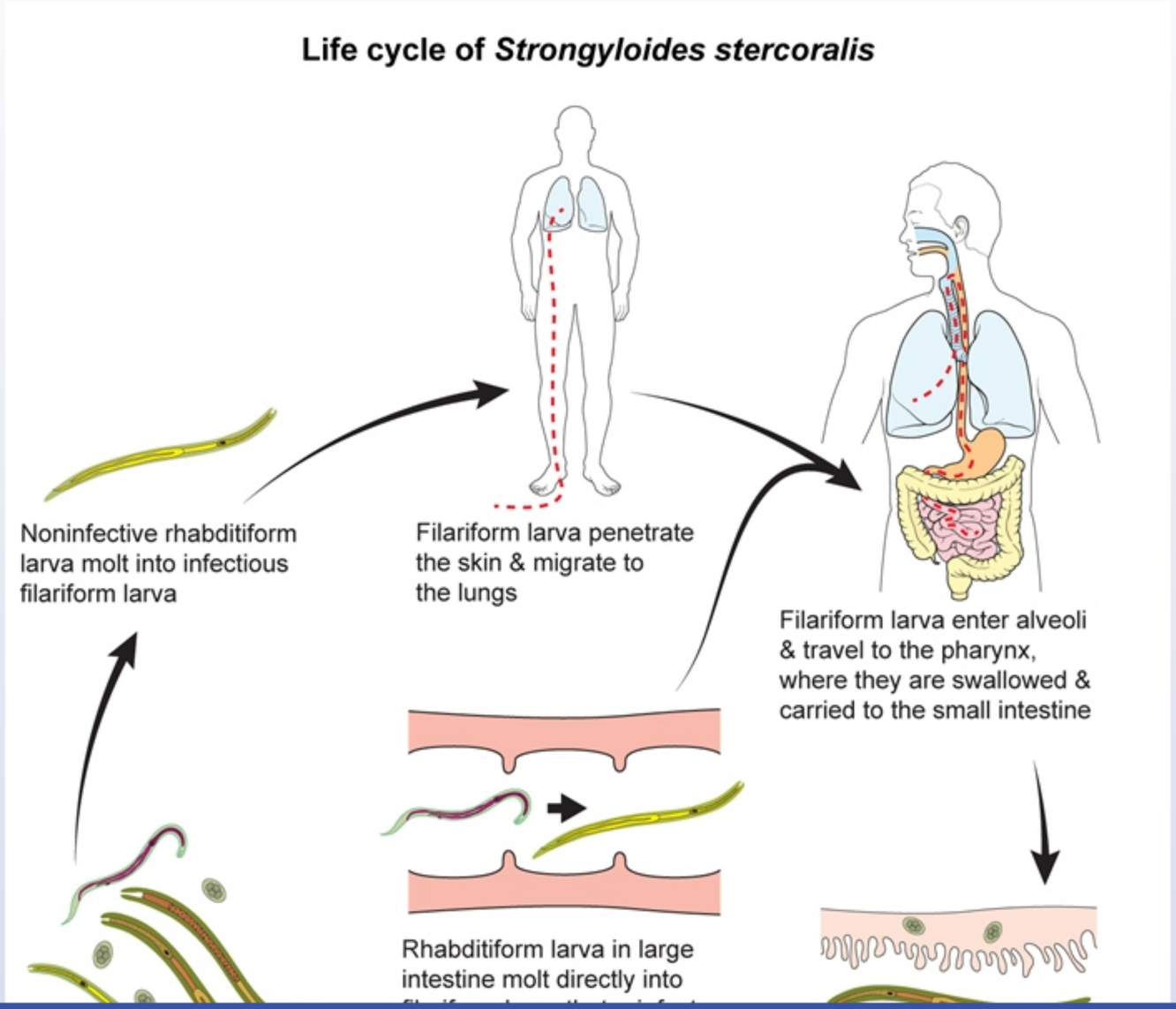

Block Time Remaining: 00:01:07
TUTOR

8 | Feedback | Suspend | End Block

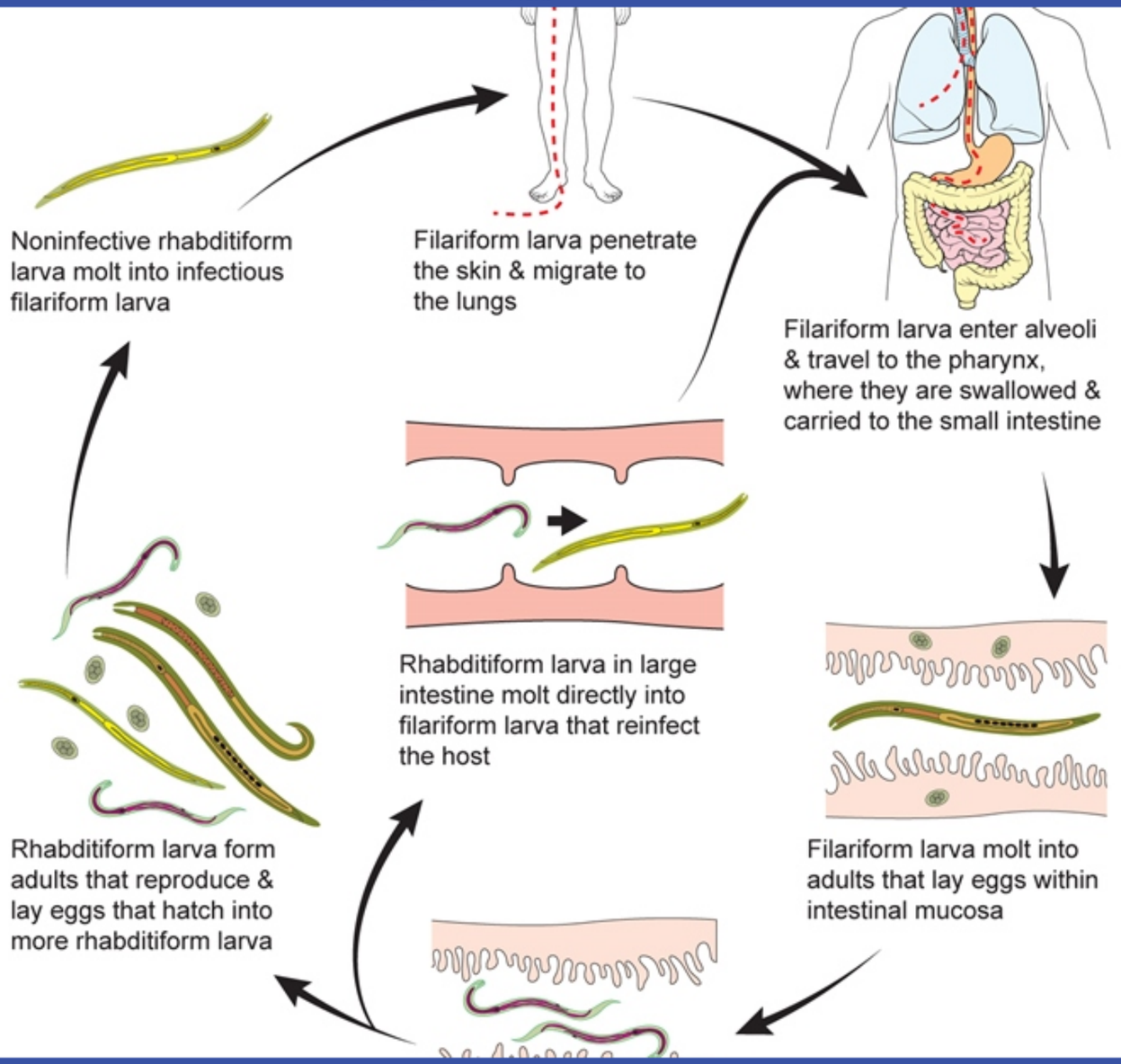
Noninfective rhabditiform larva molt into infectious filariform larva
Filariform larva penetrate the skin & migrate to the lungs
Filariform larva enter alveoli & travel to the pharynx, where they are swallowed & carried to the small intestine
Filariform larva molt into adults that lay eggs within intestinal mucosa
Rhabditiform larva in large intestine molt directly into filariform larva that reinfect the host
Rhabditiform larva form adults that reproduce & lay eggs that hatch into more rhabditiform larva

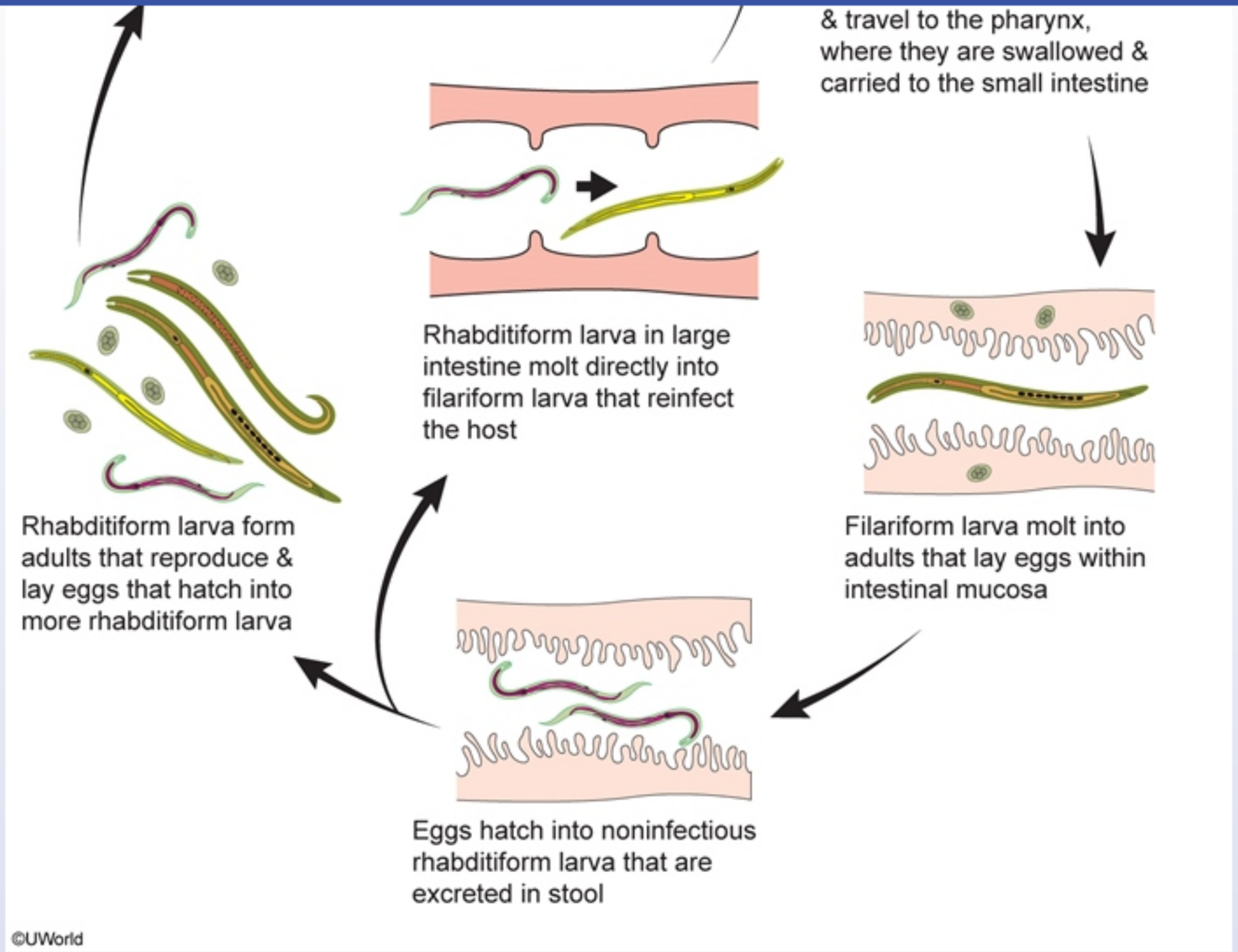

Strongyloidiasis is a disease caused by the roundworm *Strongyloides stercoralis*. The infection is transmitted by filariform (infectious) larvae found in soil contaminated with human feces. On contact, the larvae **penetrate the skin** and migrate hematogenously to the lungs. There they enter the alveoli and travel up the bronchial tree to the pharynx, where they are swallowed. When the larvae reach the intestine, they develop into

Strongyloidiasis is a disease caused by the roundworm *Strongyloides stercoralis*. The infection is transmitted by filariform (infectious) larvae found in soil contaminated with human feces. On contact, the larvae **penetrate the skin** and migrate hematogenously to the lungs. There they enter the alveoli and travel up the bronchial tree to the pharynx, where they are swallowed. When the larvae reach the intestine, they develop into adults that lay eggs within the intestinal mucosa. These hatch into rhabditiform (noninfectious) larvae that migrate into the intestinal lumen to be excreted in the stool.

Some rhabditiform larvae can molt directly into filariform larva within the intestine and re-infect the host by penetrating the intestinal wall or perianal skin. This cycle of **autoinfection** can result in a massive increase in worm burden, leading to widespread dissemination of the parasites throughout the body (**hyperinfection**). The ensuing inflammation can be severe enough to cause multiorgan dysfunction and septic shock. Hyperinfection occurs most often in patients taking immunosuppressants (eg, corticosteroids) or with HTLV-1 infection. These patients have impaired T_H2-directed cellular immunity (mediated by the antihelmintic action of eosinophils and basophils).

Strongyloidiasis occurs most commonly in tropical and warm temperate regions, particularly Southeast Asia. Most patients are asymptomatic, but some present with chronic, intermittent gastrointestinal or pulmonary symptoms. Pruritic, erythematous, linear streaks (known as **larva currens**) may occur on the thighs and buttocks as the larva migrate subcutaneously away from the perianal region. The diagnosis is made by finding rhabditiform larvae in the stool, as the eggs and adult parasites are usually seen only in intestinal biopsies. Treatment is with **ivermectin**.

(Choice A) Detection of parasite eggs in the stool is used to diagnose schistosomiasis caused by *Schistosoma mansoni* or *S japonicum*. *S stercoralis* eggs typically hatch within the intestinal mucosa and are not found in stool.

(Choice B) *Enterobius vermicularis* (pinworms) migrate out of the anus at night to deposit eggs on the surrounding perianal folds. Pinworm eggs are best detected by examining a piece of scotch tape applied to the perianal region shortly after awakening.

(Choice C) Intestinal tapeworms (eg, *Taenia solium*, *T saginata*, *Diphyllobothrium latum*) are flatworms made up of multiple segments called proglottids. These are shed from the distal end of the worm and can be detected in the stool of infected individuals.

(Choice E) Trophozoites and cysts are seen in the stool of patients with intestinal protozoal infections such as *Giardia lamblia* and *Entamoeba histolytica*.

Educational objective:
Strongyloides stercoralis infection begins following **skin penetration** by filariform (infectious) larva and can be diagnosed by finding rhabditiform

Strongyloidiasis occurs most commonly in tropical and warm temperate regions, particularly Southeast Asia. Most patients are asymptomatic, but some present with chronic, intermittent gastrointestinal or pulmonary symptoms. Pruritic, erythematous, linear streaks (known as **larva currens**) may occur on the thighs and buttocks as the larva migrate subcutaneously away from the perianal region. The diagnosis is made by finding rhabditiform larvae in the stool, as the eggs and adult parasites are usually seen only in intestinal biopsies. Treatment is with **ivermectin**.

(Choice A) Detection of parasite eggs in the stool is used to diagnose schistosomiasis caused by *Schistosoma mansoni* or *S japonicum*. *S stercoralis* eggs typically hatch within the intestinal mucosa and are not found in stool.

(Choice B) *Enterobius vermicularis* (pinworms) migrate out of the anus at night to deposit eggs on the surrounding perianal folds. Pinworm eggs are best detected by examining a piece of scotch tape applied to the perianal region shortly after awakening.

(Choice C) Intestinal tapeworms (eg, *Taenia solium*, *T saginata*, *Diphyllobothrium latum*) are flatworms made up of multiple segments called proglottids. These are shed from the distal end of the worm and can be detected in the stool of infected individuals.

(Choice E) Trophozoites and cysts are seen in the stool of patients with intestinal protozoal infections such as *Giardia lamblia* and *Entamoeba histolytica*.

Educational objective:
Strongyloides stercoralis infection begins following **skin penetration** by filariform (infectious) larva and can be diagnosed by finding rhabditiform (noninfectious) **larvae in the stool**. Rhabditiform larvae can mature into filariform larva in the human gastrointestinal tract, precipitating an autoinfection cycle that occurs entirely within the affected individual. This can result in a **hyperinfection syndrome** characterized by massive dissemination of the organism, leading to multiorgan dysfunction and septic shock.

References

- Strongyloides stercoralis in the immunocompromised population.

Microbiology	Gastrointestinal & Nutrition	Strongyloides
Subject	System	Topic

Copyright © UWorld. All rights reserved.

Settings

1 2 3 4 5 6 7 8 9 10 11 12 13 14 15 16 17 18 19 20 21 22 23 24 25 26 27 28 29 30

Item 32 of 38
Question Id: 8873

Mark | Previous | Next | Full Screen | Tutorial | Lab Values | Notes | Calculator | Reverse Color | Text Zoom | Settings

Strongyloidiasis occurs most commonly in tropical and warm temperate regions, particularly Southeast Asia. Most patients are asymptomatic, but

Exhibit Display

Zoom In | Zoom Out | Reset | Add To New Card | Existing Card

Block Time Remaining: 00:01:07
TUTOR

8 | Feedback | Suspend | End Block

Settings

1 2 3 4 5 6 7 8 9 10 11 12 13 14 15 16 17 18 19 20 21 22 23 24 25 26 27 28 29 30

Item 32 of 38
Question Id: 8873

Mark | Previous | Next | Full Screen | Tutorial | Lab Values | Notes | Calculator | Reverse Color | Text Zoom | Settings

Strongyloidiasis occurs most commonly in tropical and warm temperate regions, particularly Southeast Asia. Most patients are asymptomatic, but

Exhibit Display

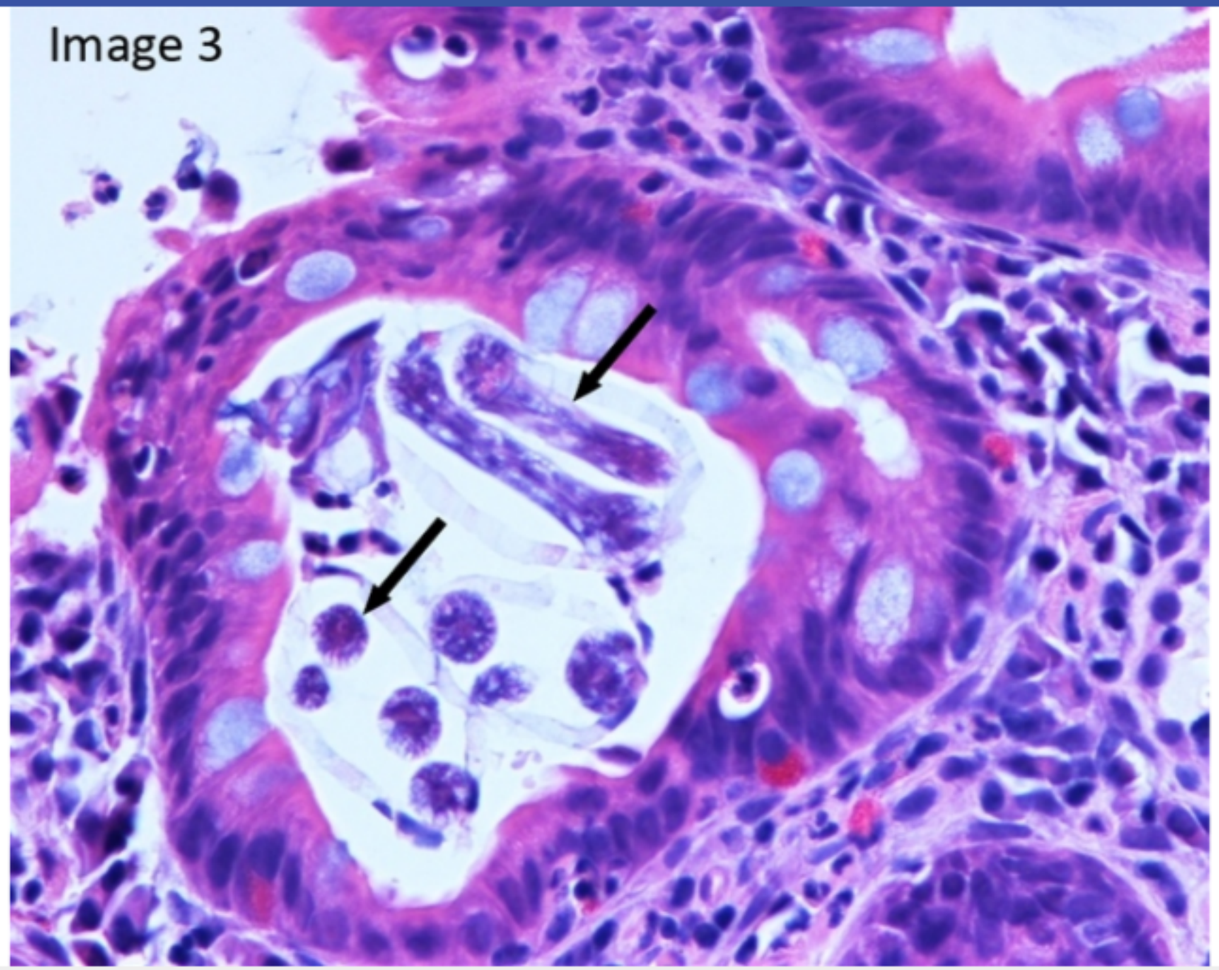

Zoom In | Zoom Out | Reset | Add To New Card | Existing Card

Block Time Remaining: 00:01:07
TUTOR

8 | Feedback | Suspend | End Block

Settings

1 2 3 4 5 6 7 8 9 10 11 12 13 14 15 16 17 18 19 20 21 22 23 24 25 26 27 28 29 30

Item 32 of 38
Question Id: 8873

Mark | Previous | Next | Full Screen | Tutorial | Lab Values | Notes | Calculator | Reverse Color | Text Zoom | Settings

Strongyloidiasis occurs most commonly in tropical and warm temperate regions, particularly Southeast Asia. Most patients are asymptomatic, but

Exhibit Display

Zoom In | Zoom Out | Reset | Add To New Card | Existing Card

Block Time Remaining: 00:01:07
TUTOR

8 | Feedback | Suspend | End Block

Settings

1 2 3 4 5 6 7 8 9 10 11 12 13 14 15 16 17 18 19 20 21 22 23 24 25 26 27 28 29 30

Item 32 of 38
Question Id: 8873

Mark | Previous | Next | Full Screen | Tutorial | Lab Values | Notes | Calculator | Reverse Color | Text Zoom | Settings

Strongyloidiasis occurs most commonly in tropical and warm temperate regions, particularly Southeast Asia. Most patients are asymptomatic, but

Exhibit Display

Giardia trophozoite and cysts Giardia trophozoite and cysts

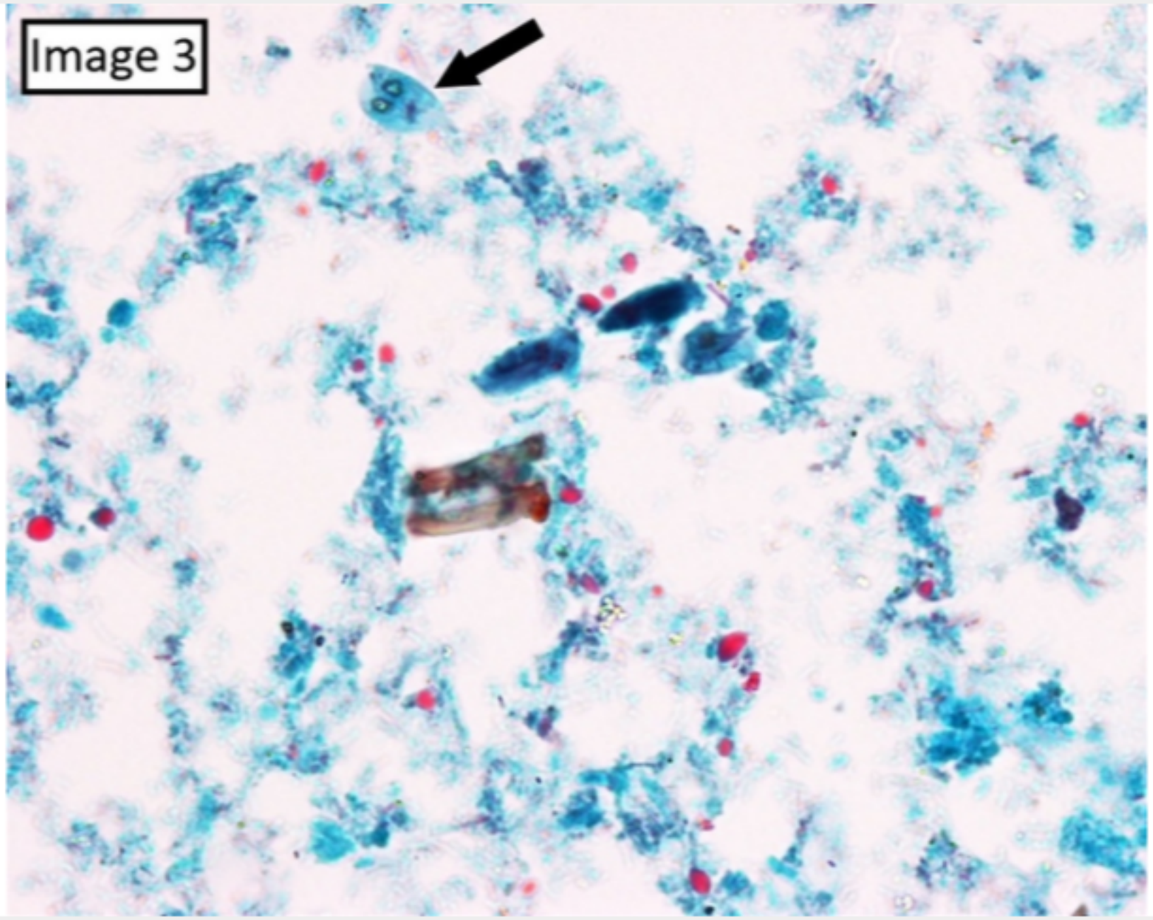

Zoom In | Zoom Out | Reset | Add To New Card | Existing Card

Block Time Remaining: 00:01:07
TUTOR

8 | Feedback | Suspend | End Block

Settings

1 2 3 4 5 6 7 8 9 10 11 12 13 14 15 16 17 18 19 20 21 22 23 24 25 26 27 28 29 30

Item 32 of 38
Question Id: 8873

Mark | Previous | Next | Full Screen | Tutorial | Lab Values | Notes | Calculator | Reverse Color | Text Zoom | Settings

Strongyloidiasis occurs most commonly in tropical and warm temperate regions, particularly Southeast Asia. Most patients are asymptomatic, but

Exhibit Display

Giardia trophozoite and cysts Giardia trophozoite and cysts

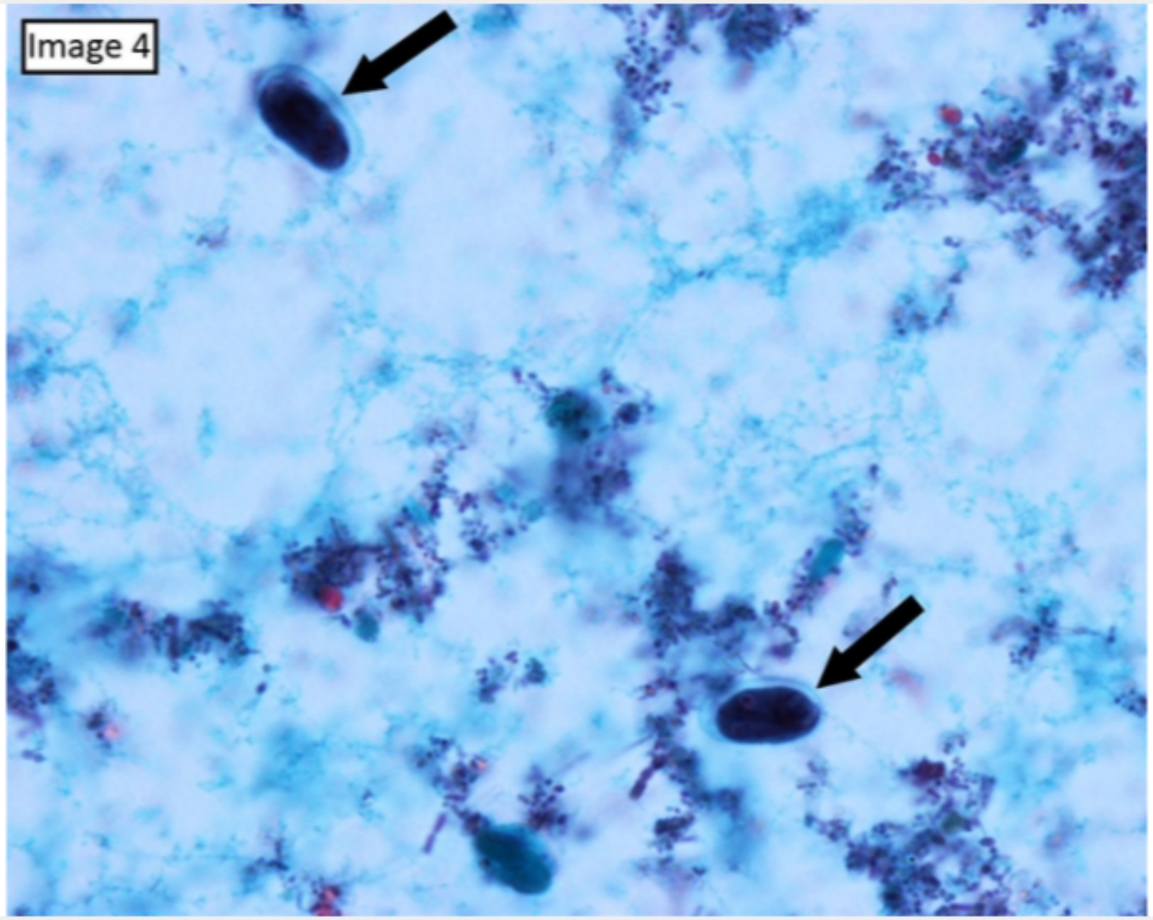

Zoom In | Zoom Out | Reset | Add To New Card | Existing Card

Block Time Remaining: 00:01:07
TUTOR

8 | Feedback | Suspend | End Block

A 10-year-old boy is brought to the emergency department after experiencing high fevers and chills for the last few days. He also complains of dull pain just above his left knee. He has no history of recent trauma other than minor scrapes to his knees and elbows while playing outside. Physical examination shows point tenderness 3 cm above the kneecap. There is no joint effusion. Radiographs show soft-tissue swelling and a periosteal reaction over the lower end of the femur. Which of the following organisms is most likely responsible for this patient's symptoms?

- A. *Enterococcus faecalis*
- B. *Moraxella catarrhalis*
- C. *Staphylococcus aureus*
- D. *Staphylococcus epidermidis*
- E. *Streptococcus agalactiae*
- F. *Streptococcus pneumoniae*
- G. *Streptococcus pyogenes*

Submit

A 10-year-old boy is brought to the emergency department after experiencing high fevers and chills for the last few days. He also complains of dull pain just above his left knee. He has no history of recent trauma other than minor scrapes to his knees and elbows while playing outside. Physical examination shows point tenderness 3 cm above the kneecap. There is no joint effusion. Radiographs show soft-tissue swelling and a periosteal reaction over the lower end of the femur. Which of the following organisms is most likely responsible for this patient's symptoms?

- A. *Enterococcus faecalis* (0%)
- B. *Moraxella catarrhalis* (1%)
- ✓ C. *Staphylococcus aureus* (84%)
- D. *Staphylococcus epidermidis* (4%)
- E. *Streptococcus agalactiae* (0%)
- F. *Streptococcus pneumoniae* (1%)
- G. *Streptococcus pyogenes* (6%)

Omitted
Correct answer
C

84%
Answered correctly

02 secs
Time Spent

07/01/2020
Last Updated

Explanation

Causes of osteomyelitis

Causes of osteomyelitis

Associated condition	Mode of infection	Most frequent pathogen	Typical location
Childhood age	Hematogenous seeding during an episode of bacteremia	*Staphylococcus aureus*	Long bones
Sickle cell disease	Hematogenous seeding to infarcted bone	*Salmonella* *Staphylococcus aureus*	Long bones
Pott disease	Hematogenous seeding from lungs	*Mycobacterium tuberculosis*	Vertebrae
Diabetes mellitus	Contiguous spread from infected foot ulcer	Polymicrobial	Bones of the feet
Recumbent patients with impaired mobility	Contiguous spread from pressure sores	Polymicrobial	Sacrum & heels
Recent trauma or orthopedic surgery	Direct inoculation	Polymicrobial	Variable

©UWorld

©UWorld

Osteomyelitis is an infection of bone and bone marrow that occurs by 1 of 3 mechanisms:

1. Hematogenous seeding due to an episode of bacteremia
2. Spread from a contiguous focus of infection, as occurs in an infected diabetic foot wound
3. Direct inoculation of bone, such as with a compound fracture

Hematogenous osteomyelitis occurs predominantly in children (particularly boys) and most frequently affects the long bones. The tibia, fibula, and femur are most often involved. Adults who develop the condition are more likely to have vertebral involvement and frequently have a predisposition to bacteremia due to risk factors such as IV drug abuse or indwelling vascular catheters.

The presenting symptoms of hematogenous osteomyelitis are vague, and a high index of suspicion is required to make the diagnosis. Initial symptoms such as malaise and fevers are non-specific. As the infection progresses, infants and younger children may refuse to move the affected extremity. Older children often complain of pain over a long bone. Bone pain develops as the abscess expands within the bone, leading to bone necrosis, periosteal disruption, and swelling of the surrounding soft tissue. ***Staphylococcus aureus*** is implicated in most cases of acute hematogenous osteomyelitis in otherwise healthy children.

(Choice A) *Enterococcus faecalis* causes a variety of infections, including endocarditis, meningitis, and urinary tract infections. *Enterococcus* can cause vertebral osteomyelitis after a recent urinary tract infection via bacteremic spread.

(Choice B) *Moraxella catarrhalis* is a part of the normal flora of the upper respiratory tract. It causes otitis media and sinusitis in healthy individuals and is frequently responsible for causing exacerbation of chronic obstructive pulmonary disease.

(Choice D) *Staphylococcus epidermidis* is ubiquitous in nature and is commonly isolated in cultures as a contaminant. However, *S epidermidis* can also be pathogenic, colonizing intravenous catheters and other foreign bodies such as prosthetic heart valves and orthopedic hardware, leading to bacteremia and sepsis.

(Choice E) *Streptococcus agalactiae* (group B streptococcus) frequently colonizes the gastrointestinal and urogenital tracts. Infants born vaginally to colonized mothers can develop serious neonatal infections, including sepsis, pneumonia, and meningitis. For this reason, pregnant women testing positive for group B streptococci are treated with antibiotic prophylaxis during labor and delivery.

(Choice A) *Enterococcus faecalis* causes a variety of infections, including endocarditis, meningitis, and urinary tract infections. *Enterococcus* can cause vertebral osteomyelitis after a recent urinary tract infection via bacteremic spread.

(Choice B) *Moraxella catarrhalis* is a part of the normal flora of the upper respiratory tract. It causes otitis media and sinusitis in healthy individuals and is frequently responsible for causing exacerbation of chronic obstructive pulmonary disease.

(Choice D) *Staphylococcus epidermidis* is ubiquitous in nature and is commonly isolated in cultures as a contaminant. However, *S epidermidis* can also be pathogenic, colonizing intravenous catheters and other foreign bodies such as prosthetic heart valves and orthopedic hardware, leading to bacteremia and sepsis.

(Choice E) *Streptococcus agalactiae* (group B streptococcus) frequently colonizes the gastrointestinal and urogenital tracts. Infants born vaginally to colonized mothers can develop serious neonatal infections, including sepsis, pneumonia, and meningitis. For this reason, pregnant women testing positive for group B streptococci are treated with antibiotic prophylaxis during labor and delivery.

(Choice F) *Streptococcus pneumoniae* is the most common etiologic agent of community-acquired pneumonia. It also causes otitis media in children, sinusitis, meningitis, and sepsis.

(Choice G) After *Staphylococcus aureus, Streptococcus pyogenes* (group A streptococcus) is the second most common cause of hematogenous osteomyelitis in children. Group A streptococci are also responsible for streptococcal pharyngitis and skin infections such as impetigo and necrotizing fasciitis.

Educational objective:
Hematogenous osteomyelitis is predominantly a disease of children that most frequently affects the long bones. *Staphylococcus aureus* is implicated in most cases secondary to a bacteremic event. *Streptococcus pyogenes* (group A streptococcus) is the second most common cause of hematogenous osteomyelitis.

Microbiology	Rheumatology/Orthopedics & Sports	Osteomyelitis
Subject	System	Topic

Copyright © UWorld. All rights reserved.

An 8-year-old boy is brought to the emergency department due to 2 days of fever, abdominal pain, and diarrhea. The patient has no significant medical history and has received all recommended vaccinations. He attends a primary school and has not traveled recently. The family recently brought home a new puppy from a kennel. The patient's stool is positive for occult blood but negative for ova and parasites. Which of the following is the most likely cause of this patient's symptoms?

A. *Bacillus cereus*

B. *Campylobacter*

C. *Giardia lamblia*

D. Norovirus

E. *Staphylococcus aureus*

F. *Vibrio parahaemolyticus*

Submit

An 8-year-old boy is brought to the emergency department due to 2 days of fever, abdominal pain, and diarrhea. The patient has no significant medical history and has received all recommended vaccinations. He attends a primary school and has not traveled recently. The family recently brought home a new puppy from a kennel. The patient's stool is positive for occult blood but negative for ova and parasites. Which of the following is the most likely cause of this patient's symptoms?

A. *Bacillus cereus* (4%)

✓ B. *Campylobacter* (58%)

C. *Giardia lamblia* (6%)

D. Norovirus (17%)

E. *Staphylococcus aureus* (1%)

F. *Vibrio parahaemolyticus* (11%)

Omitted
Correct answer
B

58%
Answered correctly

02 secs
Time Spent

01/17/2020
Last Updated

Explanation

Campylobacter jejuni is a motile, curved, gram-negative rod that is a leading cause of gastroenteritis. The pathogen resides in the gastrointestinal tract of warm-blooded animals and is primarily transmitted to humans due to ingestion of contaminated food, particularly undercooked poultry. However, direct contact with **domesticated animals** (eg, dogs) is another important source of transmission; puppies from kennels are especially likely to harbor the bacteria.

Campylobacter jejuni is a motile, curved, gram-negative rod that is a leading cause of gastroenteritis. The pathogen resides in the gastrointestinal tract of warm-blooded animals and is primarily transmitted to humans due to ingestion of contaminated food, particularly undercooked poultry. However, direct contact with **domesticated animals** (eg, dogs) is another important source of transmission; puppies from kennels are especially likely to harbor the bacteria.

Following ingestion, *Campylobacter* colonizes the intestinal mucosa, enters enterocytes within endocytic vacuoles, and causes cytotoxic injury due to specific virulence factors (eg, cytolethal distending toxin, lipooligosaccharide). Patients typically develop fever, crampy abdominal pain, and watery **diarrhea** that may be bloody. Stool studies will show **inflammation** (leukocytes, erythrocytes) but no ova or parasites; stool culture is diagnostic (enriched media at 42 C [107.6 F] and microaerophilic conditions). Manifestations usually resolve spontaneously in 3-5 days. In a minority of cases, the host response to *Campylobacter* infection generates cross-reacting antibodies to peripheral nerve myelin gangliosides, leading to Guillain-Barré syndrome.

(Choices A and E) *Bacillus cereus* and *Staphylococcus aureus* cause enterotoxin-mediated food-borne illness. Ingestion of the preformed toxin leads to rapid-onset nausea, vomiting, and abdominal pain (diarrhea can occur but is usually mild). *S aureus* food-borne illness is often linked to precooked foods, dairy products, custards, and mayonnaise-based salads; *B cereus* food-borne illness is often associated with starch-based foods, such as reheated rice.

(Choice C) *Giardia lamblia* is usually transmitted by drinking contaminated water. Foodborne or person-to-person spread may also occur. Giardia typically causes foul-smelling, watery diarrhea that is noninflammatory; therefore, no fecal blood or leukocytes are typically present. In addition, stool ova and parasite testing often reveals *Giardia* trophozoites or cysts.

(Choice D) Norovirus is the most common cause of viral gastroenteritis and is usually transmitted due to food or water contaminated with human feces. Patients typically develop a vomiting-predominant illness with abdominal pain and a moderate amount of watery diarrhea. However, the pathogen is noninflammatory and therefore no stool blood or leukocytes are seen.

(Choice F) *Vibrio parahaemolyticus* lives in marine environments and is typically transmitted via contaminated seafood (eg, shellfish). Manifestations include a diarrhea-predominant gastroenteritis. Life-threatening sepsis can occur in those with liver disease or hemachromatosis.

Educational objective:
Campylobacter infection is a common cause of gastroenteritis and is typically acquired from contaminated food (eg, undercooked poultry) or

diagnostic (enriched media at 42 C [107.6 F] and microaerophilic conditions). Manifestations usually resolve spontaneously in 3-5 days. In a minority of cases, the host response to *Campylobacter* infection generates cross-reacting antibodies to peripheral nerve myelin gangliosides, leading to Guillain-Barré syndrome.

(Choices A and E) *Bacillus cereus* and *Staphylococcus aureus* cause enterotoxin-mediated food-borne illness. Ingestion of the preformed toxin leads to rapid-onset nausea, vomiting, and abdominal pain (diarrhea can occur but is usually mild). *S aureus* food-borne illness is often linked to precooked foods, dairy products, custards, and mayonnaise-based salads; *B cereus* food-borne illness is often associated with starch-based foods, such as reheated rice.

(Choice C) *Giardia lamblia* is usually transmitted by drinking contaminated water. Foodborne or person-to-person spread may also occur. Giardia typically causes foul-smelling, watery diarrhea that is noninflammatory; therefore, no fecal blood or leukocytes are typically present. In addition, stool ova and parasite testing often reveals *Giardia* trophozoites or cysts.

(Choice D) Norovirus is the most common cause of viral gastroenteritis and is usually transmitted due to food or water contaminated with human feces. Patients typically develop a vomiting-predominant illness with abdominal pain and a moderate amount of watery diarrhea. However, the pathogen is noninflammatory and therefore no stool blood or leukocytes are seen.

(Choice F) *Vibrio parahaemolyticus* lives in marine environments and is typically transmitted via contaminated seafood (eg, shellfish). Manifestations include a diarrhea-predominant gastroenteritis. Life-threatening sepsis can occur in those with liver disease or hemachromatosis.

Educational objective:
Campylobacter infection is a common cause of gastroenteritis and is typically acquired from contaminated food (eg, undercooked poultry) or domesticated animals (eg, household dogs). Manifestations usually include fever, cramping abdominal pain, and watery diarrhea that may be bloody. Stool studies typically show blood and leukocytes. *Campylobacter* infection is associated with Guillain-Barré syndrome.

Microbiology	Gastrointestinal & Nutrition	Acute diarrhea
Subject	System	Topic

Copyright © UWorld. All rights reserved.

A 64-year-old man comes to the office due to 2 days of dysuria, urinary frequency, and urgency. He recently underwent a cystoscopy for evaluation of hematuria. The patient has a history of hypertension, type 2 diabetes mellitus, and 30 pack-years of cigarette smoking. His temperature is 38.2 C (100.8 F). On examination, there is suprapubic tenderness on deep palpation but no costovertebral angle tenderness. Urinalysis findings are as follows:

Leukocyte esterase	positive
Nitrites	negative
Bacteria	many
White blood cells	20-30/hpf
Red blood cells	many/hpf

Midstream urine culture grows gram-positive cocci in chains with growth >100,000 colony-forming units/mL. The organism responsible for this patient's condition is most likely to demonstrate which of the following?

A. Ability to decompose hydrogen peroxide
B. Gamma hemolysis on blood agar
C. Growth only in absence of oxygen
D. Possession of cytochrome oxidase
E. Production of golden yellow pigments

Submit

A 64-year-old man comes to the office due to 2 days of dysuria, urinary frequency, and urgency. He recently underwent a cystoscopy for evaluation of hematuria. The patient has a history of hypertension, type 2 diabetes mellitus, and 30 pack-years of cigarette smoking. His temperature is 38.2 C (100.8 F). On examination, there is suprapubic tenderness on deep palpation but no costovertebral angle tenderness. Urinalysis findings are as follows:

Leukocyte esterase	positive
Nitrites	negative
Bacteria	many
White blood cells	20-30/hpf
Red blood cells	many/hpf

Midstream urine culture grows gram-positive cocci in chains with growth >100,000 colony-forming units/mL. The organism responsible for this patient's condition is most likely to demonstrate which of the following?

A. Ability to decompose hydrogen peroxide (20%)
✓ B. Gamma hemolysis on blood agar (55%)
C. Growth only in absence of oxygen (4%)
D. Possession of cytochrome oxidase (8%)
E. Production of golden yellow pigments (11%)

Omitted | 55% | 01 sec | 06/05/2020

Microbiological laboratory identification of streptococci

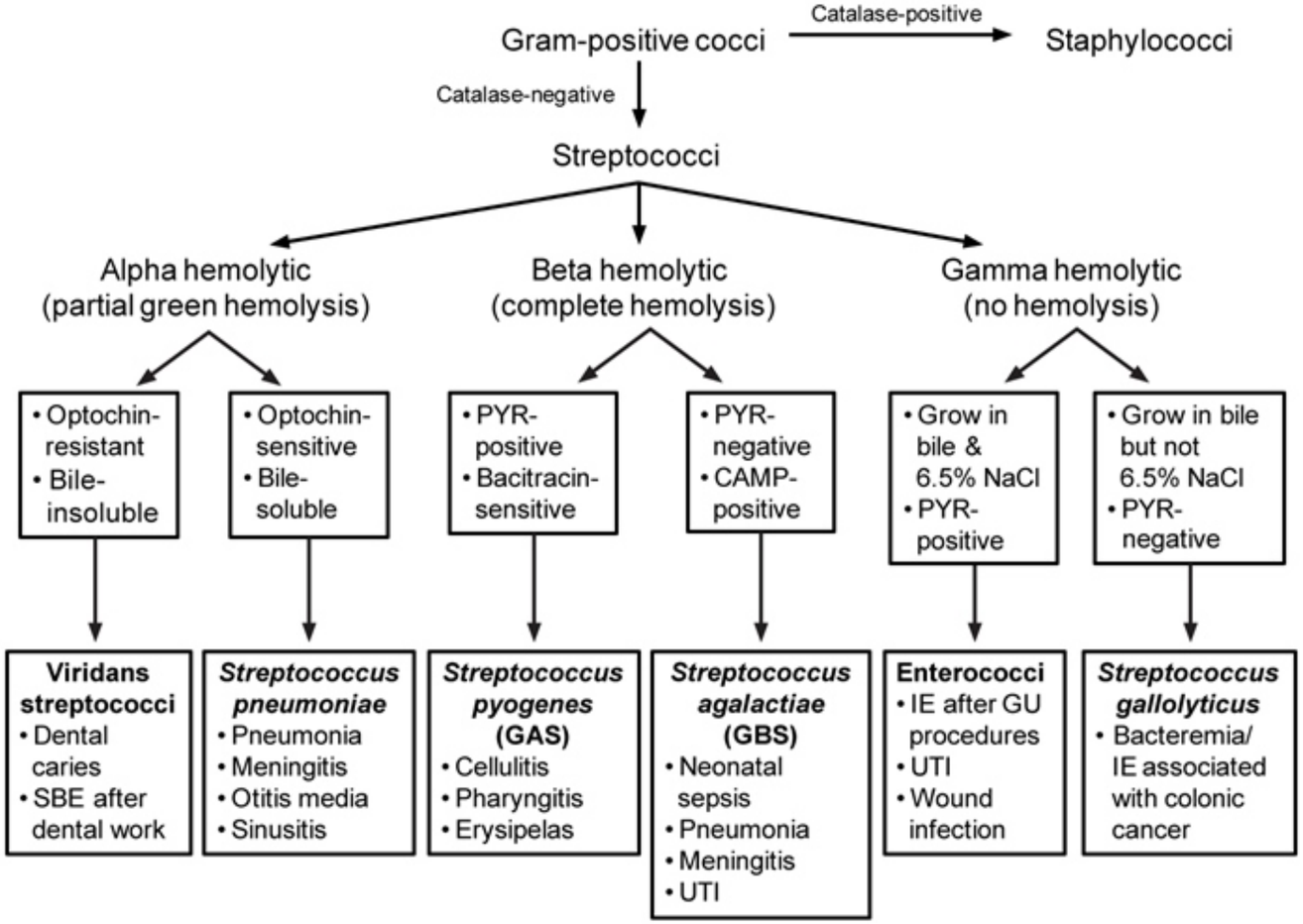

A number of species were formally reclassified from the genus *Streptococcus* to the genus *Enterococcus*, but enterococci are included here under streptococci for simplicity.

CAMP = Christie, Atkins, and Munch-Petersen test; **GAS** = group A streptococci; **GBS** = group B streptococci;

CAMP = Christie, Atkins, and Munch-Petersen test; **GAS** = group A streptococci; **GBS** = group B streptococci; **GU** = genitourinary; **IE** = infective endocarditis; **NaCl** = sodium chloride; **PYR** = pyrrolidonyl arylamidase; **SBE** = subacute bacterial endocarditis; **UTI** = urinary tract infection.

©UWorld

This patient who recently underwent a genitourinary procedure (cystoscopy) has a urinary tract infection caused by ***Enterococcus***. This organism has a morphology of **gram-positive cocci** in pairs and chains and, when grown on blood agar, reveals no hemolysis (**gamma hemolysis**). Other characteristics of enterococci include pyrrolidonyl arylamidase (PYR) positivity and ability to grow in bile and in 6.5% sodium chloride. They are unable to convert nitrates to nitrites, explaining this patient's negative result on urinalysis nitrite.

Enterococci are part of the normal intestinal flora of humans and animals. *Enterococcus faecalis* and *E faecium* are the most prevalent species cultured from humans and can cause urinary tract infection, bacteremia/endocarditis, wound infection, or intraabdominal or pelvic infection in the nosocomial setting. Enterococci have both intrinsic (beta-lactams, macrolides, aminoglycosides, trimethoprim-sulfamethoxazole) and acquired (vancomycin) resistance to antibiotics, making them important nosocomial pathogens.

(Choice A) The ability to decompose hydrogen peroxide is suggestive of the presence of catalase, which would indicate *Staphylococcus* (which are gram-positive cocci in clusters not chains).

(Choice C) Enterococci are aerobic organisms. Examples of anaerobic gram-positive cocci include *Peptostreptococcus* and *Micrococcus*.

(Choice D) Oxidase positivity (possession of cytochrome oxidase) can help identify certain gram-negative organisms (eg, *Pseudomonas*).

(Choice E) *Staphylococcus aureus* produces golden yellow pigments. Other bacteria producing pigments include *Pseudomonas aeruginosa* (blue-green) and *Serratia marcescens* (red).

Educational objective:
Enterococcus is an important cause of urinary tract infections. These organisms are gram-positive cocci in pairs and chains and, when grown on blood agar, they do not cause hemolysis (gamma-hemolytic).

References

- Emergence of Enterococcus as a significant pathogen.
- The life and times of the Enterococcus.

A 36-year-old immigrant from Peru comes to the office due to difficulty swallowing liquids. He also has difficulty belching. Eating slowly and extending the neck partially relieves his symptoms. The patient has had no fever, weight loss, chest pain, cough, dyspnea, or neurologic symptoms. He has no chronic medical problems and takes no medications. He has been an active smoker for the last 18 years but does not use alcohol or illicit drugs. The patient is afebrile with normal vital signs. BMI is 24 kg/m^2. On examination, the abdomen is soft, nondistended, and nontender, with no masses or organomegaly. Bowel sounds are normal. Other examination findings are unremarkable. Barium swallow shows a dilated esophagus, and manometry confirms absent peristalsis in the smooth muscle portion of the esophagus. If this patient's symptoms are caused by an infection, which of the following organisms is the most likely cause?

- A. *Candida albicans*
- B. *Clostridium botulinum*
- C. Cytomegalovirus
- D. *Helicobacter pylori*
- E. *Schistosoma mansoni*
- F. *Trypanosoma cruzi*

Submit

A 36-year-old immigrant from Peru comes to the office due to difficulty swallowing liquids. He also has difficulty belching. Eating slowly and extending the neck partially relieves his symptoms. The patient has had no fever, weight loss, chest pain, cough, dyspnea, or neurologic symptoms. He has no chronic medical problems and takes no medications. He has been an active smoker for the last 18 years but does not use alcohol or illicit drugs. The patient is afebrile with normal vital signs. BMI is 24 kg/m^2. On examination, the abdomen is soft, nondistended, and nontender, with no masses or organomegaly. Bowel sounds are normal. Other examination findings are unremarkable. Barium swallow shows a dilated esophagus, and manometry confirms absent peristalsis in the smooth muscle portion of the esophagus. If this patient's symptoms are caused by an infection, which of the following organisms is the most likely cause?

- A. *Candida albicans* (1%)
- B. *Clostridium botulinum* (9%)
- C. Cytomegalovirus (3%)
- D. *Helicobacter pylori* (3%)
- E. *Schistosoma mansoni* (2%)
- ✓ F. *Trypanosoma cruzi* (79%)

Omitted
Correct answer
F

79%
Answered correctly

01 sec
Time Spent

02/07/2020
Last Updated

Explanation

Chagas disease	
Epidemiology	• Caused by protozoan *Trypanosoma cruzi* • Vector: triatomine ("kissing") bug • Endemic in Central & South America
Cardiac manifestations	• Dilated cardiomyopathy with biventricular failure • Apical wall thinning with aneurysm ± mural thrombus • Ventricular arrhythmias
Gastrointestinal manifestations	• Megaesophagus (secondary achalasia) • Megacolon

This patient who presents with dysphagia and a dilated esophagus has **achalasia**, which is characterized by the absence of distal esophageal peristalsis and incomplete relaxation of a hypertensive lower esophageal sphincter. It is most often a primary disorder; however, in a patient from Central or South America, secondary achalasia due to **Chagas disease** should be suspected.

Chagas disease is caused by chronic infection with *Trypanosoma cruzi*, a slender C- or U-shaped flagellated parasite with darkly staining nucleus and kinetoplast. Parasitosis-related inflammation and immune-mediated cross-reactivity between the parasite and the enteric ganglia lead to destruction of the submucosal (Meissner) and myenteric (Auerbach) plexus. Denervation results in uncoordinated smooth muscle activity, increased esophageal tone, and incomplete lower esophageal relaxation. Mechanical dilation (due to obstructed liquids and solids) proximal to the functional obstruction manifests as **megaesophagus**. Patients classically experience dysphagia progressing from solids to liquids, odynophagia (due to food impaction), difficulty belching, regurgitation, and malnutrition. Other manifestations of Chagas disease can include nonischemic **cardiomyopathy** and megacolon. In addition, patients are at higher risk for esophageal cancer.

(Choices A and C) Immunocompromised patients (eg, advanced HIV) can develop infectious esophagitis. *Candida albicans* causes exudative esophagitis, usually with concurrent oral thrush. Cytomegalovirus causes ulcerative esophagitis in the distal esophagus. Dysphagia and odynophagia are common with these disorders, but esophageal dilation and motility abnormalities are unexpected, and occurrence in immunocompetent patients is rare.

Chagas disease is caused by chronic infection with *Trypanosoma cruzi*, a slender C- or U-shaped flagellated parasite with darkly staining nucleus and kinetoplast. Parasitosis-related inflammation and immune-mediated cross-reactivity between the parasite and the enteric ganglia lead to destruction of the submucosal (Meissner) and myenteric (Auerbach) plexus. Denervation results in uncoordinated smooth muscle activity, increased esophageal tone, and incomplete lower esophageal relaxation. Mechanical dilation (due to obstructed liquids and solids) proximal to the functional obstruction manifests as **megaesophagus**. Patients classically experience dysphagia progressing from solids to liquids, odynophagia (due to food impaction), difficulty belching, regurgitation, and malnutrition. Other manifestations of Chagas disease can include nonischemic **cardiomyopathy** and megacolon. In addition, patients are at higher risk for esophageal cancer.

(Choices A and C) Immunocompromised patients (eg, advanced HIV) can develop infectious esophagitis. *Candida albicans* causes exudative esophagitis, usually with concurrent oral thrush. Cytomegalovirus causes ulcerative esophagitis in the distal esophagus. Dysphagia and odynophagia are common with these disorders, but esophageal dilation and motility abnormalities are unexpected, and occurrence in immunocompetent patients is rare.

(Choice B) *Clostridium botulinum* causes botulism, a paralytic disease resulting from neurotoxins that inhibit the release of acetylcholine from presynapatic nerve terminals. Patients develop cranial nerve dysfunction and descending muscular weakness.

(Choice D) *Helicobacter pylori* causes gastritis and peptic ulcer. Typical manifestations include epigastric pain and nausea; however, *H pylori* does not usually cause esophageal disorders and is unlikely to cause esophageal dilation or absent peristalsis.

(Choice E) *Schistosoma mansoni* is a parasite found in Asia that causes intestinal or hepatic schistosomiasis; this results in gastrointestinal illness (diarrhea, abdominal pain) or portal hypertension and cirrhosis, respectively.

Educational objective:
Chagas disease is caused by a chronic infection by *Trypanosoma cruzi* and causes secondary achalasia due to destruction of the submucosal (Meissner) and myenteric (Auerbach) plexus. Other manifestations can include nonischemic cardiomyopathy and megacolon.

Microbiology	Gastrointestinal & Nutrition	Achalasia
Subject	System	Topic

Copyright © UWorld. All rights reserved.

Settings

1 2 3 4 5 6 7 8 9 10 11 12 13 14 15 16 17 18 19 20 21 22 23 24 25 26 27 28 29 30

Item 36 of 38
Question Id: 278

Mark | Previous | Next | Full Screen | Tutorial | Lab Values | Notes | Calculator | Reverse Color | Text Zoom | Settings

- Dilated cardiomyopathy with biventricular failure

Exhibit Display

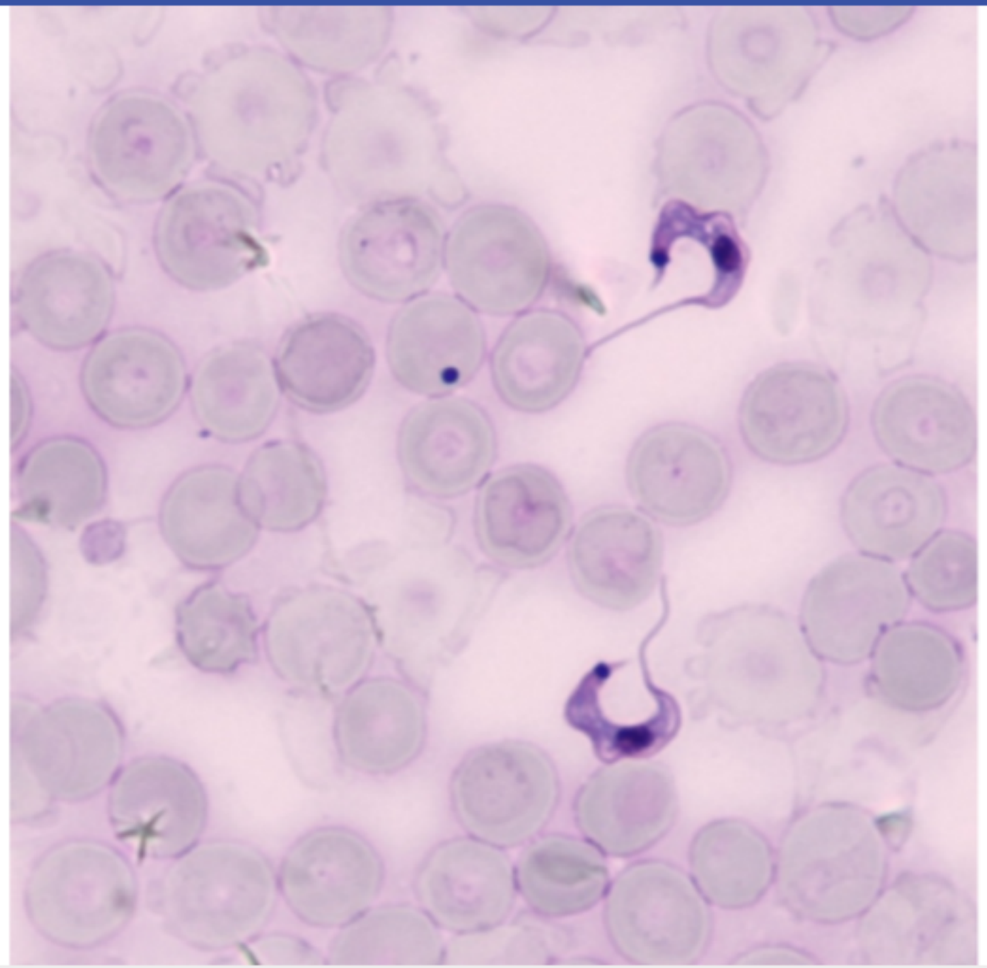

Zoom In | Zoom Out | Reset | Add To New Card | Existing Card

Block Time Remaining: 00:01:14
TUTOR

4 | Feedback | Suspend | End Block

A 46-year-old homeless man comes to the emergency department with fever and chest pain that worsens with swallowing. The patient has been hospitalized several times recently with *Pneumocystis jirovecii* pneumonia. He has a history of intravenous drug use. His temperature is 37.8 C (100 F). Oropharyngeal examination is remarkable only for poor dentition. Esophagogastroduodenoscopy is performed and reveals esophageal hyperemia and linear ulcerations. Which of the following is the most likely cause of this patient's condition?

- A. *Babesia microti*
- B. *Cryptococcus neoformans*
- C. Cytomegalovirus
- D. *Isospora belli*
- E. *Toxoplasma gondii*
- F. *Trypanosoma cruzi*
- G. Varicella zoster virus

Submit

A 46-year-old homeless man comes to the emergency department with fever and chest pain that worsens with swallowing. The patient has been hospitalized several times recently with *Pneumocystis jirovecii* pneumonia. He has a history of intravenous drug use. His temperature is 37.8 C (100 F). Oropharyngeal examination is remarkable only for poor dentition. Esophagogastroduodenoscopy is performed and reveals esophageal hyperemia and linear ulcerations. Which of the following is the most likely cause of this patient's condition?

- A. *Babesia microti* (2%)
- B. *Cryptococcus neoformans* (5%)
- ✓ C. Cytomegalovirus (77%)
- D. *Isospora belli* (3%)
- E. *Toxoplasma gondii* (2%)
- F. *Trypanosoma cruzi* (7%)
- G. Varicella zoster virus (1%)

Omitted
Correct answer
C

77%
Answered correctly

03 secs
Time Spent

02/08/2020
Last Updated

Explanation

HIV-associated esophagitis		

HIV-associated esophagitis		
Pathogen	**Endoscopic findings**	**Microscopic findings**
Candida albicans	Patches of adherent, gray/white **pseudomembranes** on erythematous mucosa	**Yeast** cells & pseudohyphae invading mucosal cells
HSV-1	Small **vesicles** → **"punched-out" ulcers**	Eosinophilic intranuclear inclusions **(Cowdry type A)** in multinuclear squamous cells at ulcer margins
CMV	**Linear** ulcerations	Intranuclear & cytoplasmic **inclusions**

CMV = cytomegalovirus; **HSV** = herpes simplex virus.

Pneumocystis jirovecii affects almost exclusively immunocompromised individuals; therefore, it is likely that this patient has HIV. He has now developed the painful swallowing characteristic of **esophagitis**. The 3 main causes of HIV-associated esophagitis are *Candida* (most common), cytomegalovirus (CMV), and herpes simplex virus (HSV). All can manifest as dysphagia (difficulty swallowing) and/or odynophagia (pain on swallowing) and can be difficult to distinguish clinically; however, accurate diagnosis is essential for treatment. **CMV esophagitis** is typically characterized endoscopically by **large, shallow linear ulcerations** (most commonly in the distal esophagus) with intranuclear and cytoplasmic inclusions seen microscopically.

(Choice A) *Babesia microti* is transmitted by a tick bite and causes babesiosis. It is endemic in the northeastern United States and manifests with flulike symptoms, hepatosplenomegaly, and anemia. It often affects asplenic patients.

(Choice B) *Cryptococcosis* causes meningitis (not esophagitis) in patients with HIV.

(Choice D) *Isospora belli* causes profuse watery diarrhea in patients with HIV. It has no role in the development of esophagitis.

Pneumocystis jirovecii affects almost exclusively immunocompromised individuals; therefore, it is likely that this patient has HIV. He has now developed the painful swallowing characteristic of **esophagitis**. The 3 main causes of HIV-associated esophagitis are *Candida* (most common), cytomegalovirus (CMV), and herpes simplex virus (HSV). All can manifest as dysphagia (difficulty swallowing) and/or odynophagia (pain on swallowing) and can be difficult to distinguish clinically; however, accurate diagnosis is essential for treatment. **CMV esophagitis** is typically characterized endoscopically by **large, shallow linear ulcerations** (most commonly in the distal esophagus) with intranuclear and cytoplasmic inclusions seen microscopically.

(Choice A) *Babesia microti* is transmitted by a tick bite and causes babesiosis. It is endemic in the northeastern United States and manifests with flulike symptoms, hepatosplenomegaly, and anemia. It often affects asplenic patients.

(Choice B) *Cryptococcosis* causes meningitis (not esophagitis) in patients with HIV.

(Choice D) *Isospora belli* causes profuse watery diarrhea in patients with HIV. It has no role in the development of esophagitis.

(Choice E) In patients with HIV, *Toxoplasma gondii* causes ring-enhancing brain lesions and chorioretinitis.

(Choice F) *Trypanosoma cruzi* causes Chagas disease (American trypanosomiasis). Chronic disease leads to cardiomyopathy, achalasia, megacolon, and megaureter.

(Choice G) HSV, not varicella zoster virus (VZV), causes esophagitis in patients with HIV. VZV causes chickenpox (varicella) and shingles (zoster).

Educational objective:
Infectious esophagitis is common in patients with HIV. The most common cause is *Candida albicans*, although cytomegalovirus and herpes simplex virus are also frequently implicated. Diagnosis is based on endoscopic and microscopic findings.

Microbiology	Gastrointestinal & Nutrition	Esophagitis
Subject	System	Topic

Copyright © UWorld. All rights reserved.

A 34-year-old woman comes to the office with recent onset of malaise. The patient reports feeling "run down and under the weather" but otherwise has no symptoms. She is an avid cyclist and is concerned about her ability to participate in a charity race in 3 days. The patient works as a nurse at a local hospital and lives at home with her husband and 2-year-old son. She occasionally smokes when she goes out, but since she began feeling ill, she no longer has the desire to smoke. Physical examination is notable for hepatomegaly. Laboratory results are as follows:

Anti-HAV IgM	positive
Anti-HAV IgG	negative
HBsAg	negative
HBeAg	negative
Anti-HBs	positive
Anti-HBc	negative
Anti-HBe	negative
Anti-HCV	negative

Which of the following is most likely to be elicited on further history taking?

- A. Had a tattoo recently at a local tattoo parlor
- B. Had an accidental needlestick exposure at work
- C. Had boiled eggs from the hospital cafeteria
- D. Had steamed oysters at a neighborhood restaurant
- E. Had unprotected sexual intercourse with a new partner

began feeling ill, she no longer has the desire to smoke. Physical examination is notable for hepatomegaly. Laboratory results are as follows:

Anti-HAV IgM	positive
Anti-HAV IgG	negative
HBsAg	negative
HBeAg	negative
Anti-HBs	positive
Anti-HBc	negative
Anti-HBe	negative
Anti-HCV	negative

Which of the following is most likely to be elicited on further history taking?

- A. Had a tattoo recently at a local tattoo parlor
- B. Had an accidental needlestick exposure at work
- C. Had boiled eggs from the hospital cafeteria
- D. Had steamed oysters at a neighborhood restaurant
- E. Had unprotected sexual intercourse with a new partner

Submit

began feeling ill, she no longer has the desire to smoke. Physical examination is notable for hepatomegaly. Laboratory results are as follows:

Anti-HAV IgM	positive
Anti-HAV IgG	negative
HBsAg	negative
HBeAg	negative
Anti-HBs	positive
Anti-HBc	negative
Anti-HBe	negative
Anti-HCV	negative

Which of the following is most likely to be elicited on further history taking?

A. Had a tattoo recently at a local tattoo parlor (1%)

B. Had an accidental needlestick exposure at work (10%)

C. Had boiled eggs from the hospital cafeteria (8%)

✓ D. Had steamed oysters at a neighborhood restaurant (75%)

E. Had unprotected sexual intercourse with a new partner (3%)

Omitted
Correct answer

75%
Answered correctly

09 secs
Time Spent

01/19/2020
Last Updated

Explanation

Hepatitis A infection is caused by an RNA picornavirus with an average incubation period of 30 days. Transmission occurs through the **fecal-oral** route and is common in areas with overcrowding and poor sanitation. Outbreaks frequently result from **contaminated water or food**, with raw or steamed **shellfish** being the typical (and classically tested) culprit in the United States. Onset is acute, and symptoms can include malaise, fatigue, anorexia, nausea, vomiting, mild abdominal pain, and an aversion to smoking (for unclear reasons). Hepatomegaly is commonly seen. Serum aminotransferases spike early in the illness, followed by increases in bilirubin and alkaline phosphatase. Anti-HAV IgM is positive and is a marker of active disease. Hepatitis A infection is a self-limiting disease and does not progress to chronic hepatitis, cirrhosis, or hepatocellular carcinoma.

Treatment is largely supportive, with complete recovery expected in 3-6 weeks. People considered at high risk (eg, those living in or traveling to endemic areas, those with chronic liver disease or clotting factor disorders, men who have sex with men) should be given the hepatitis A vaccine as prophylaxis. Unvaccinated close contacts of individuals with hepatitis A should receive the vaccine or immune globulin.

(Choices A, B, and E) Unsanitary tattooing (eg, with contaminated needles), accidental needlesticks, and unprotected sexual intercourse are important risk factors for hepatitis B and C. This patient is positive for HBsAb, which confirms that she has antibodies to hepatitis B surface antigen and, given the negative anti-HBc, suggests that she has been vaccinated and is now immune.

(Choice C) The consumption of boiled eggs is not commonly associated with hepatitis A infection. If the boiled eggs were insufficiently cooked, *Salmonella* infection would be a risk.

Educational objective:
Transmission of the hepatitis A virus occurs through the fecal-oral route and is common in areas with overcrowding and poor sanitation. Outbreaks frequently result from contaminated water or food, and raw or steamed shellfish is a common culprit in the United States.

References

- Risk assessment in shellfish-borne outbreaks of hepatitis A.

Microbiology	Gastrointestinal & Nutrition	Hepatitis a
Subject	System	Topic

route and is common in areas with overcrowding and poor sanitation. Outbreaks frequently result from **contaminated water or food**, with raw or steamed **shellfish** being the typical (and classically tested) culprit in the United States. Onset is acute, and symptoms can include malaise, fatigue, anorexia, nausea, vomiting, mild abdominal pain, and an aversion to smoking (for unclear reasons). Hepatomegaly is commonly seen. Serum aminotransferases spike early in the illness, followed by increases in bilirubin and alkaline phosphatase. Anti-HAV IgM is positive and is a marker of active disease. Hepatitis A infection is a self-limiting disease and does not progress to chronic hepatitis, cirrhosis, or hepatocellular carcinoma.

Treatment is largely supportive, with complete recovery expected in 3-6 weeks. People considered at high risk (eg, those living in or traveling to endemic areas, those with chronic liver disease or clotting factor disorders, men who have sex with men) should be given the hepatitis A vaccine as prophylaxis. Unvaccinated close contacts of individuals with hepatitis A should receive the vaccine or immune globulin.

(Choices A, B, and E) Unsanitary tattooing (eg, with contaminated needles), accidental needlesticks, and unprotected sexual intercourse are important risk factors for hepatitis B and C. This patient is positive for HBsAb, which confirms that she has antibodies to hepatitis B surface antigen and, given the negative anti-HBc, suggests that she has been vaccinated and is now immune.

(Choice C) The consumption of boiled eggs is not commonly associated with hepatitis A infection. If the boiled eggs were insufficiently cooked, *Salmonella* infection would be a risk.

Educational objective:
Transmission of the hepatitis A virus occurs through the fecal-oral route and is common in areas with overcrowding and poor sanitation. Outbreaks frequently result from contaminated water or food, and raw or steamed shellfish is a common culprit in the United States.

References

- Risk assessment in shellfish-borne outbreaks of hepatitis A.

Microbiology	Gastrointestinal & Nutrition	Hepatitis a
Subject	System	Topic

Copyright © UWorld. All rights reserved.